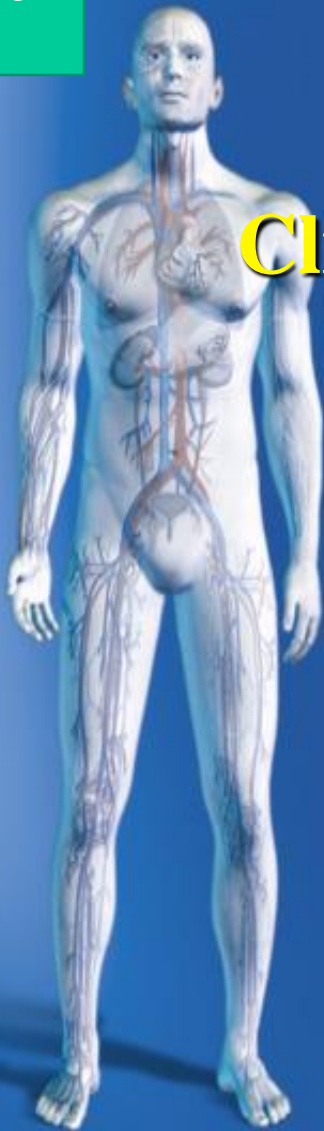

CACVS 2020



# Pharmaco-Mechanical Thrombectomy in Real Life ! Clinical Cases, What Will You Do?

**ALI AMIN MD, FACS, FACC, RVT**

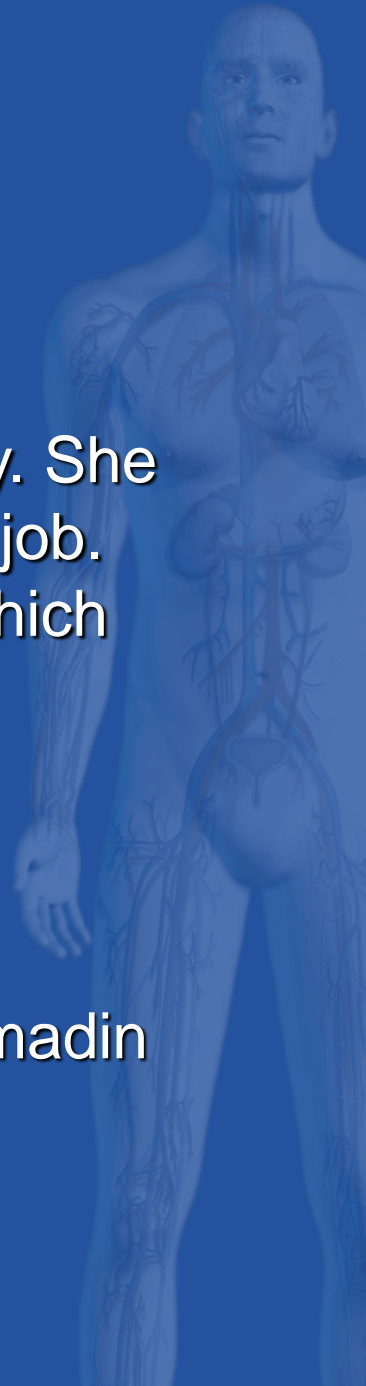**CHIEF OF ENDOVASCULAR  
INTERVENTIONS**

**READING HOSPITAL AND MEDICAL  
CENTER**

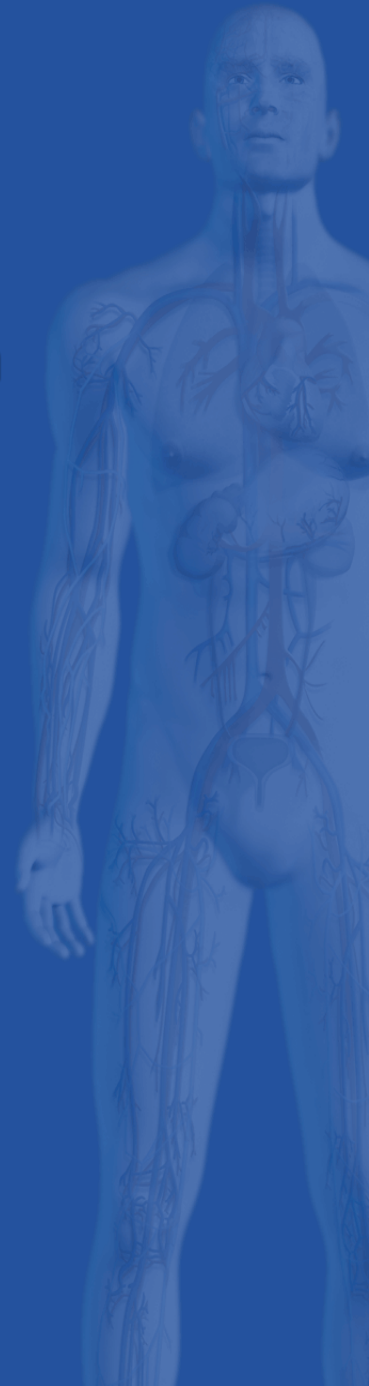
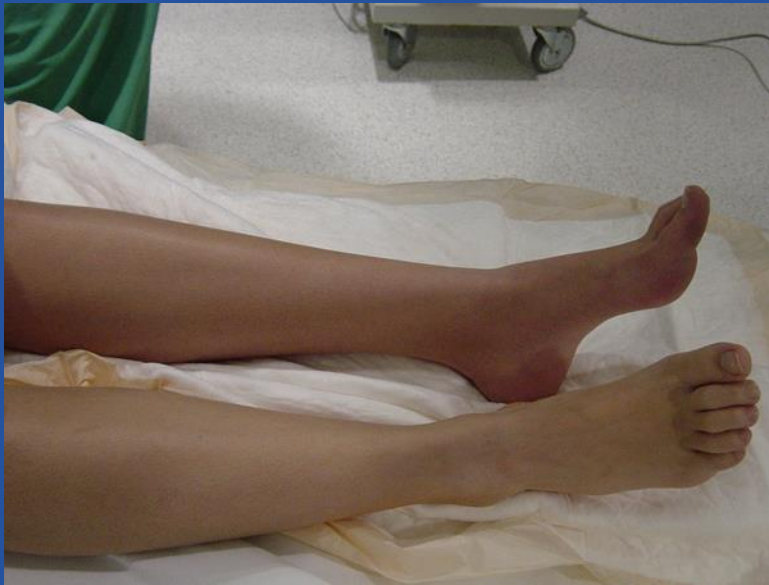**READING, PA, USA**

# Left LE DVT

- 49 Yr old female S/P elective Left foot surgery. She is executive VP and travels frequently for her job. Few days later started with left leg swelling which got worse and now involves the thigh
- PMH: No HTM, DM, No meds, No smoking
- Venous duplex scan: Left ilio-femoral DVT
- On heparin drip and received 2 doses of coumadin

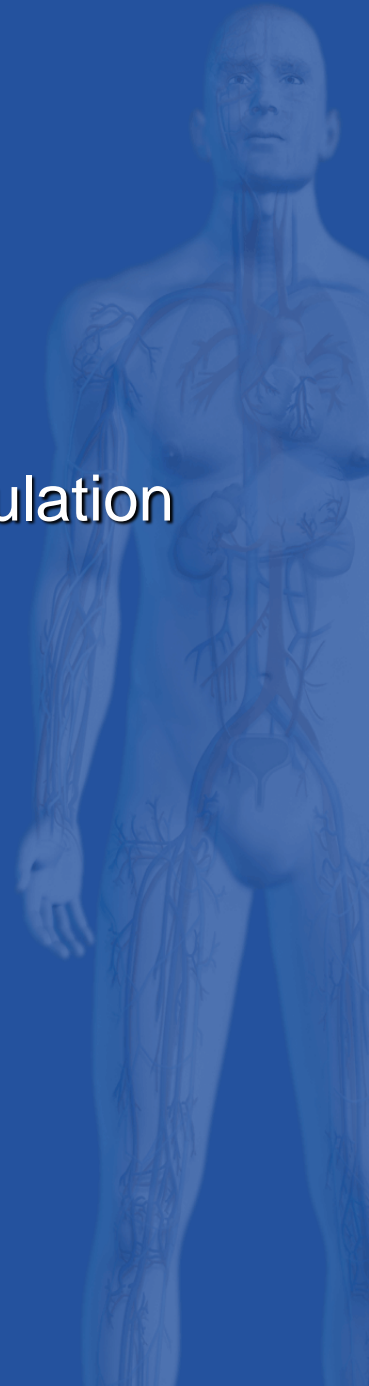

- Left foot swelling, painful to put shoe on



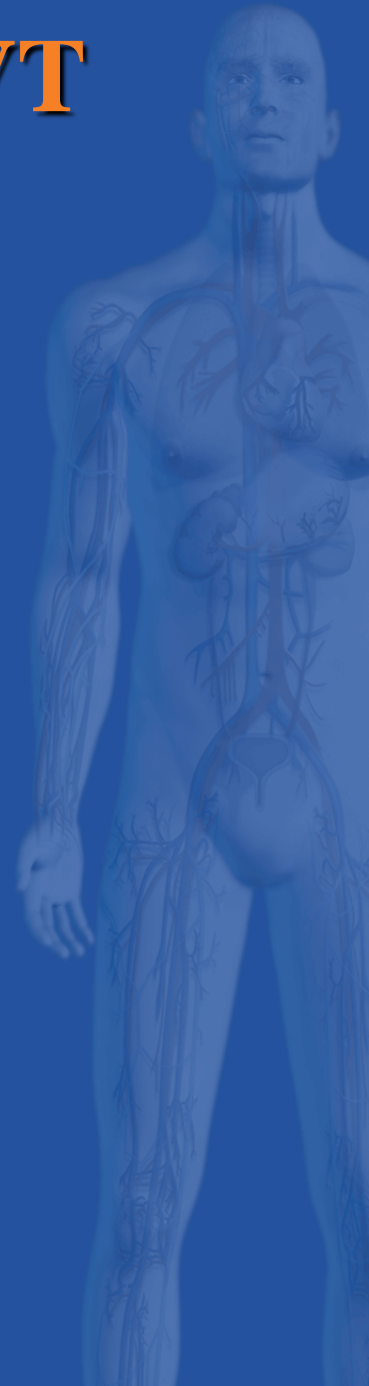
# Options ???

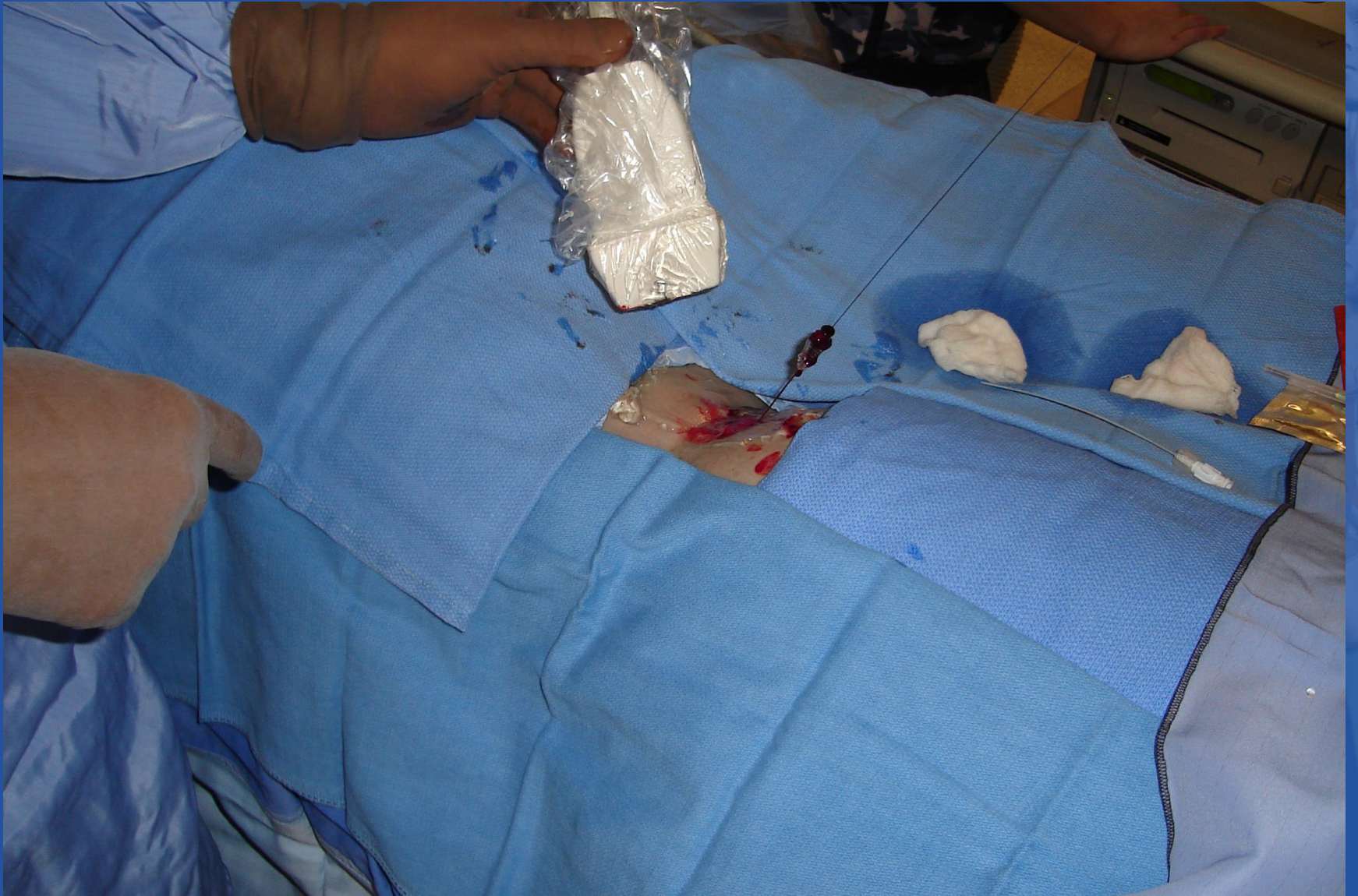- Medical management: Discharge on anticoagulation and support stockings
- Intervention: Thrombolysis
- Intervention: mechanical thrombectomy and thrombolysis

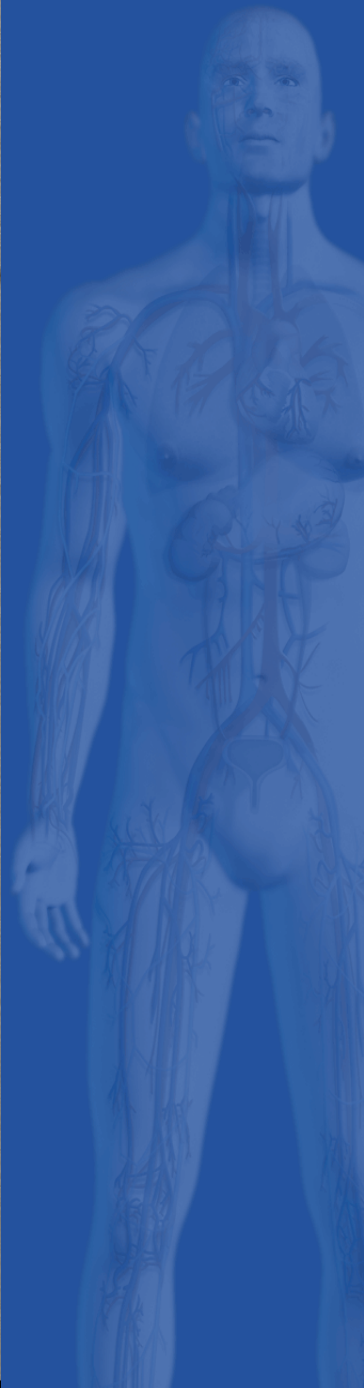

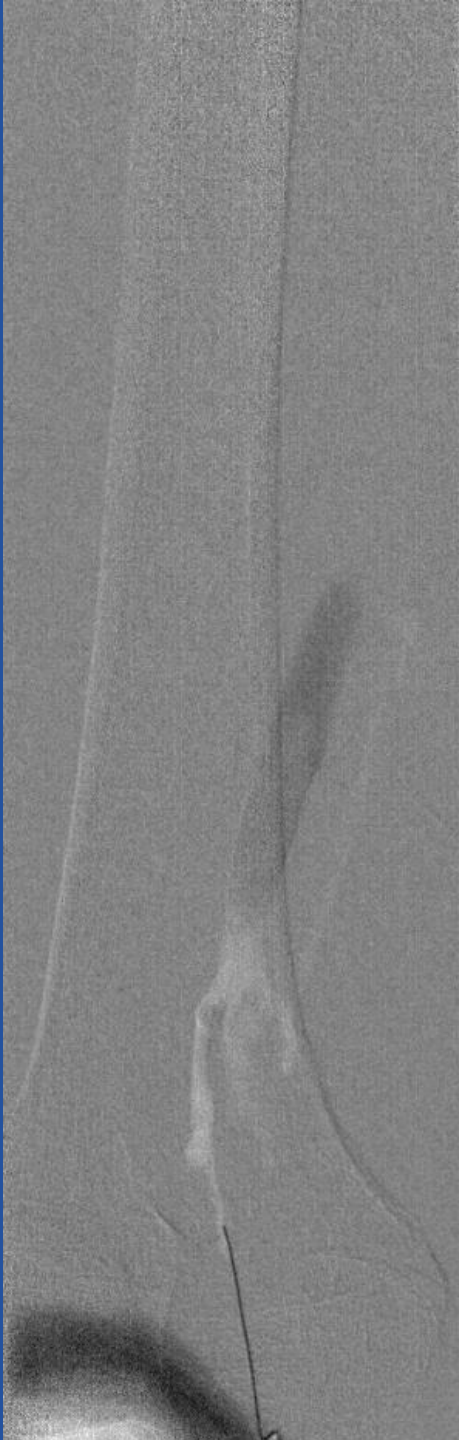


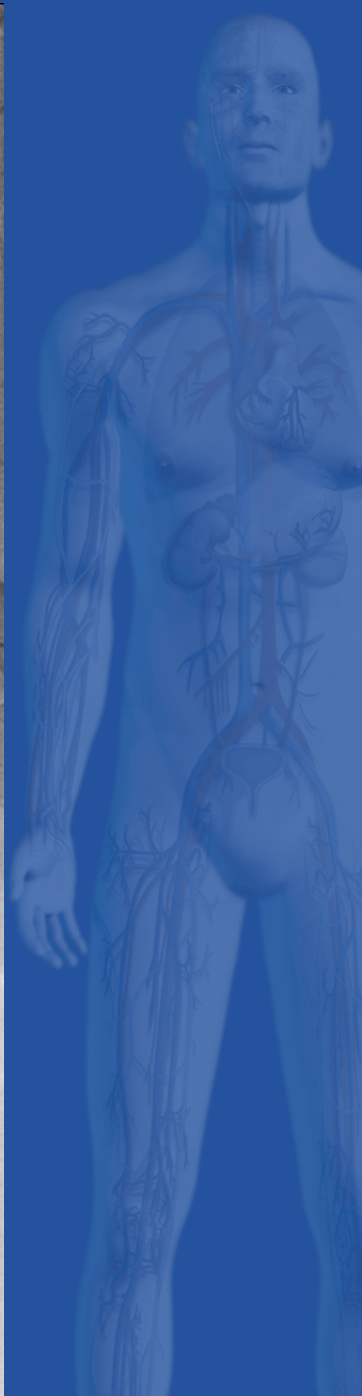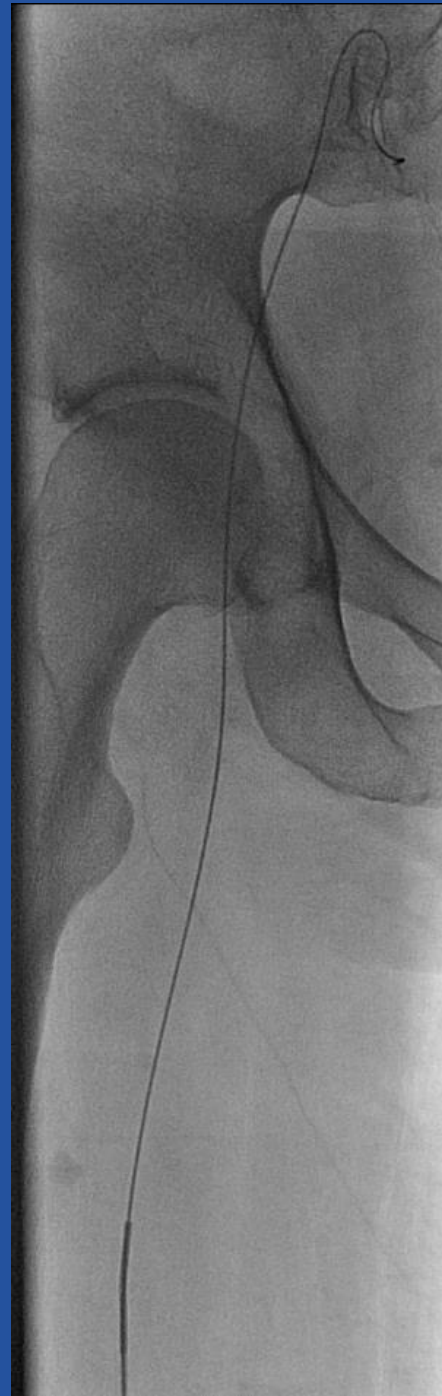

# Access ??? Left Ilio-Femoral DVT

- Left Popliteal vein
- Left posterior tibial vein
- Left small saphenous vein
- Contralateral Right CFV
- Internal jugular vein

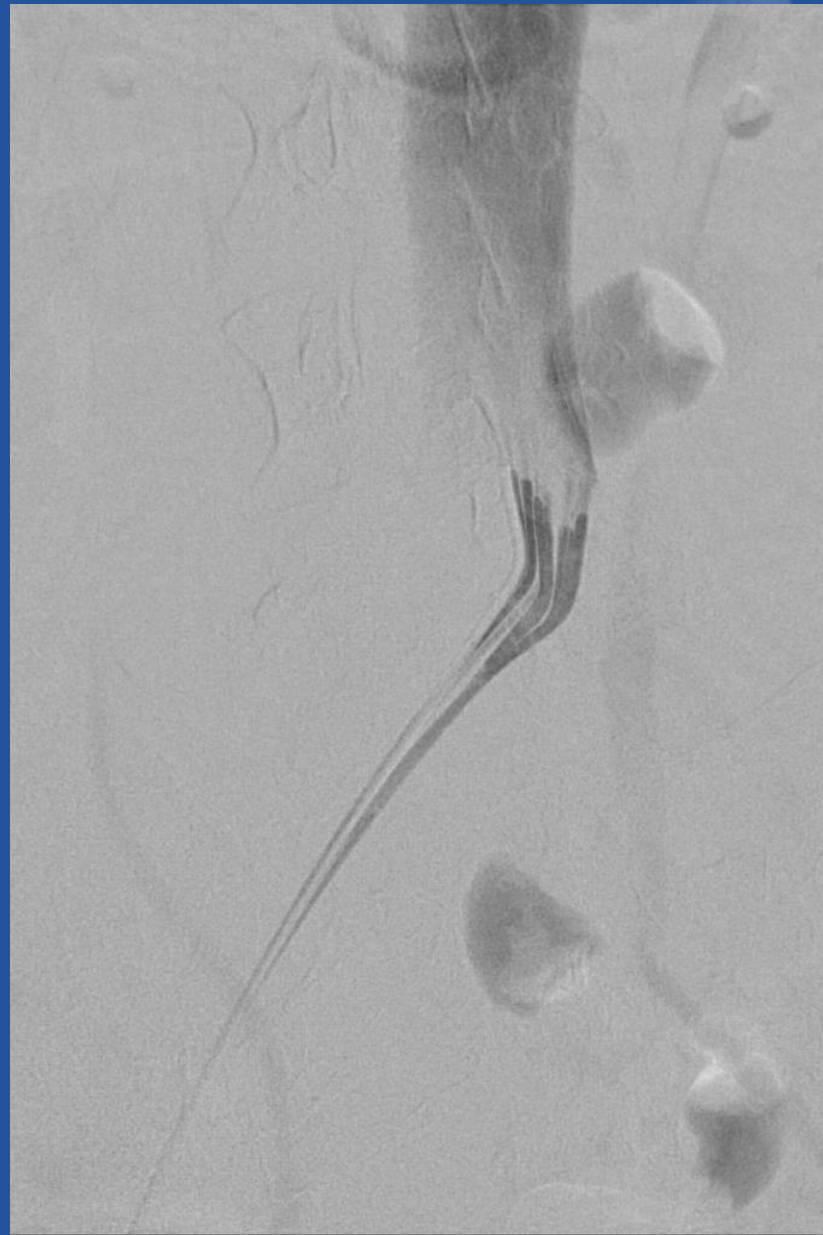
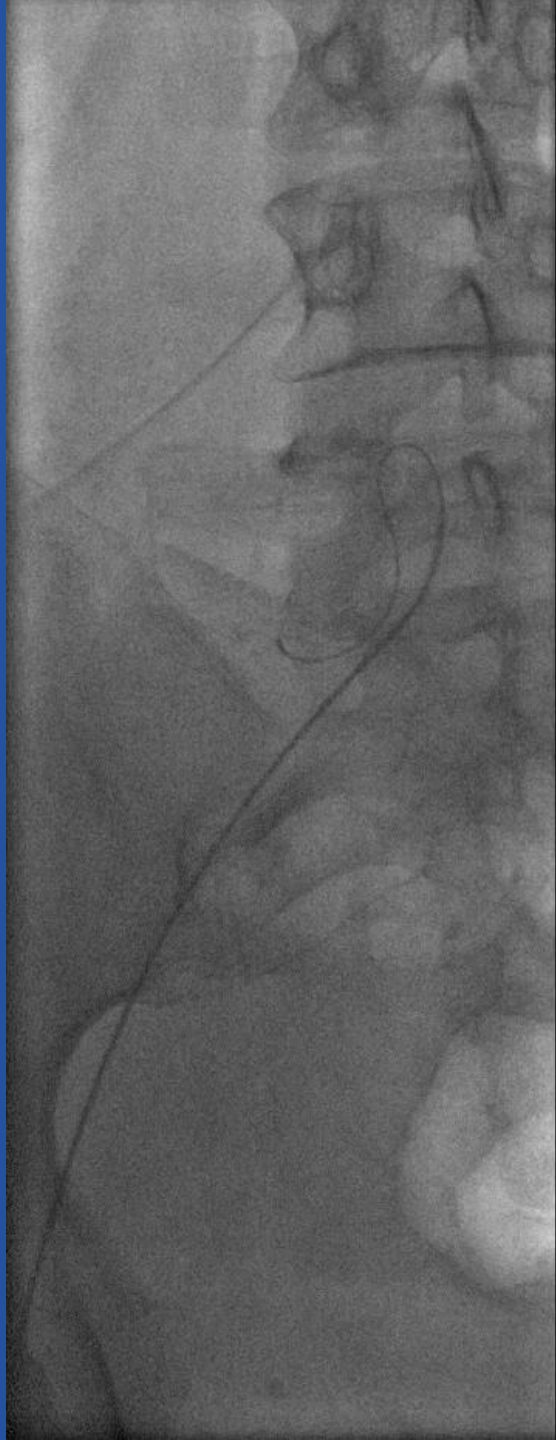
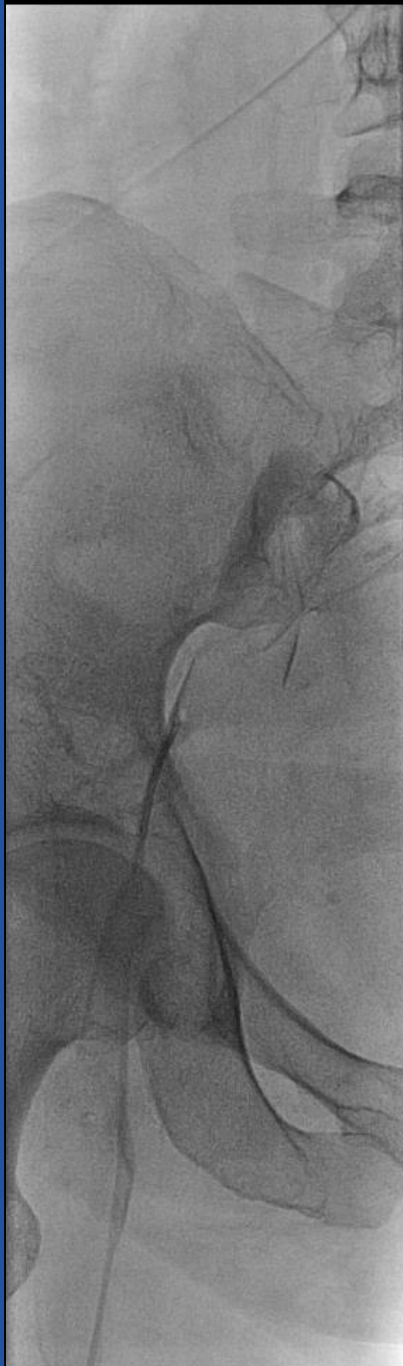











# Tool Box

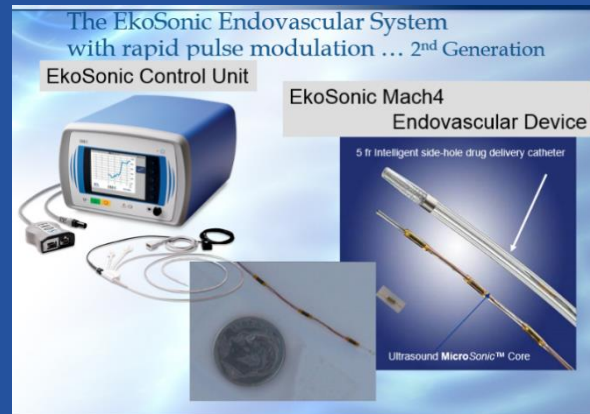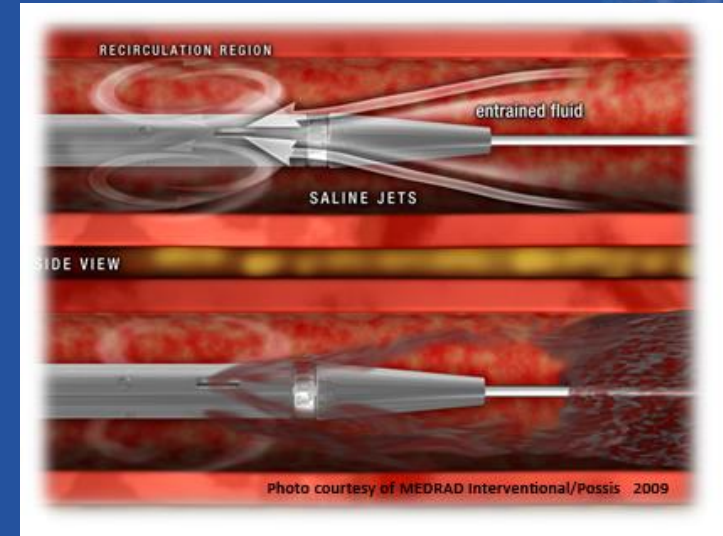
- Thrombolytic Agents

  - 1) tPA

  - 2) rPA

- Mechanical Thrombectomy catheter/Aspiration Devices

- Infusion Catheter

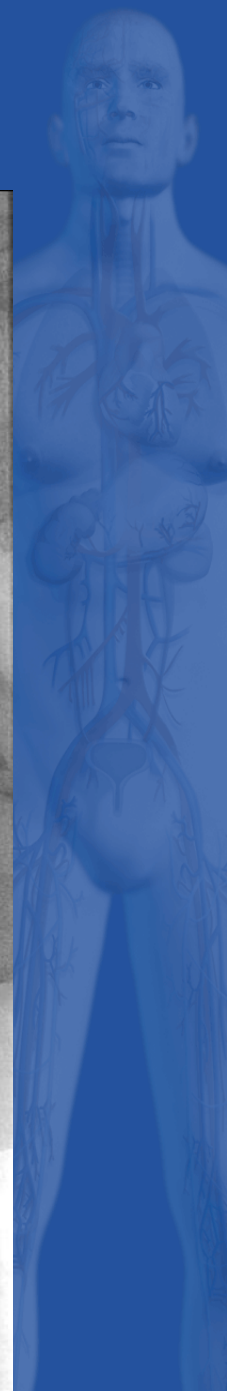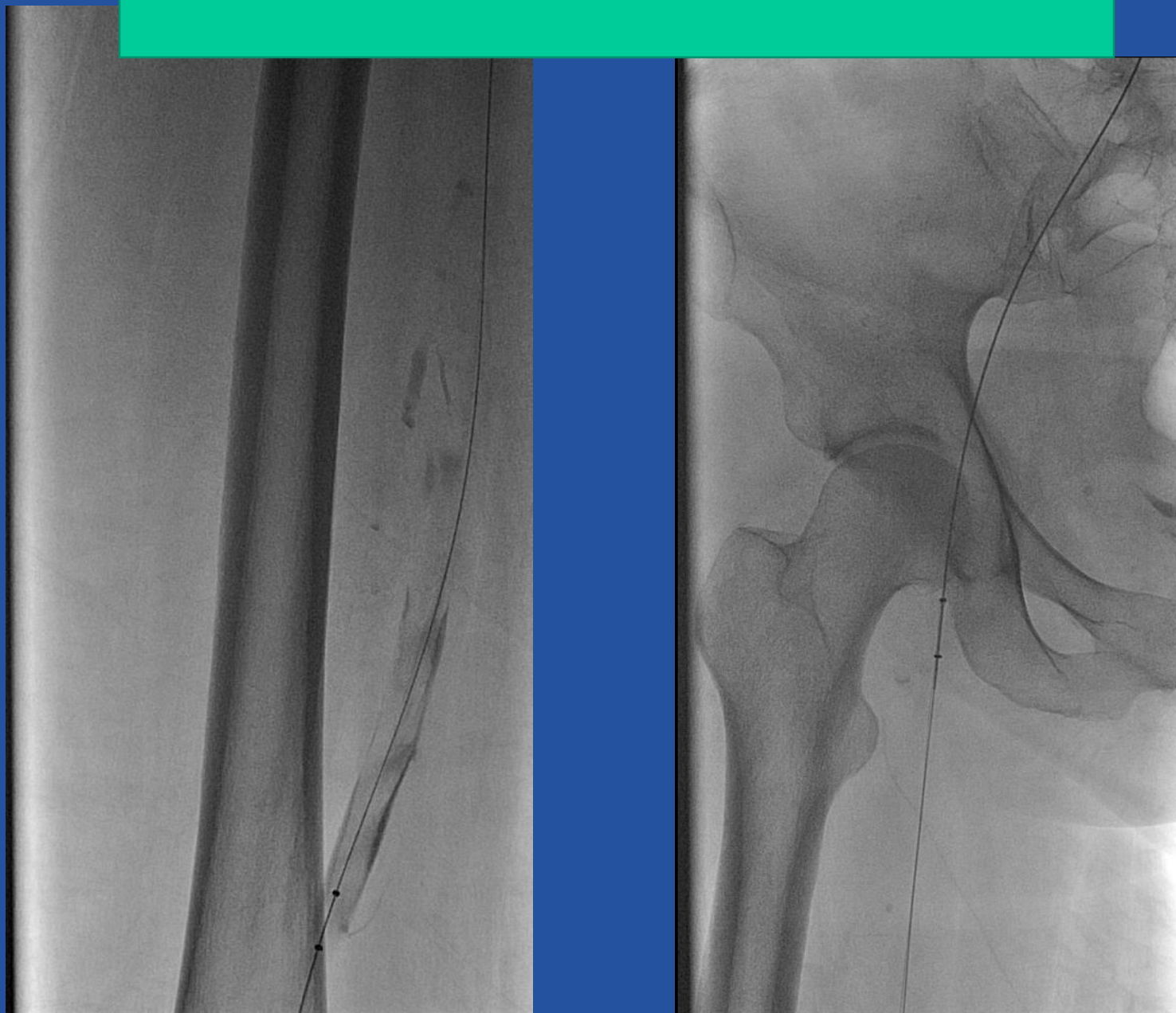


## Indigo System

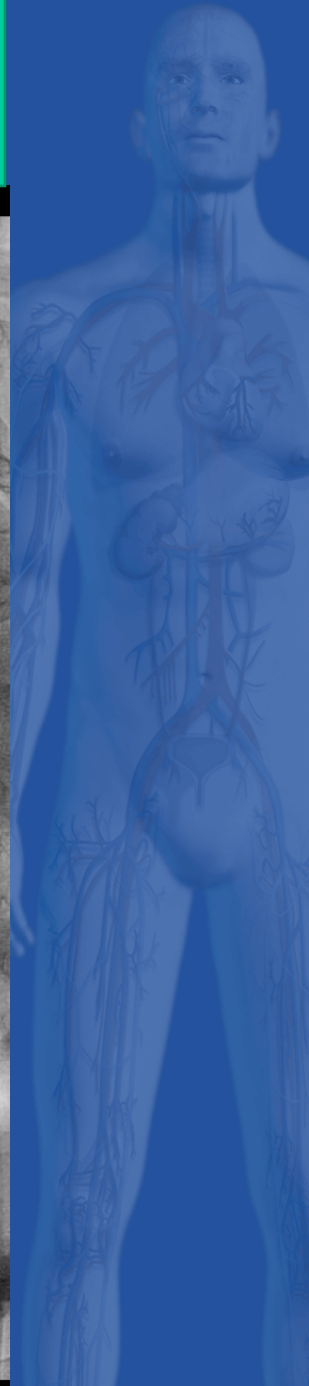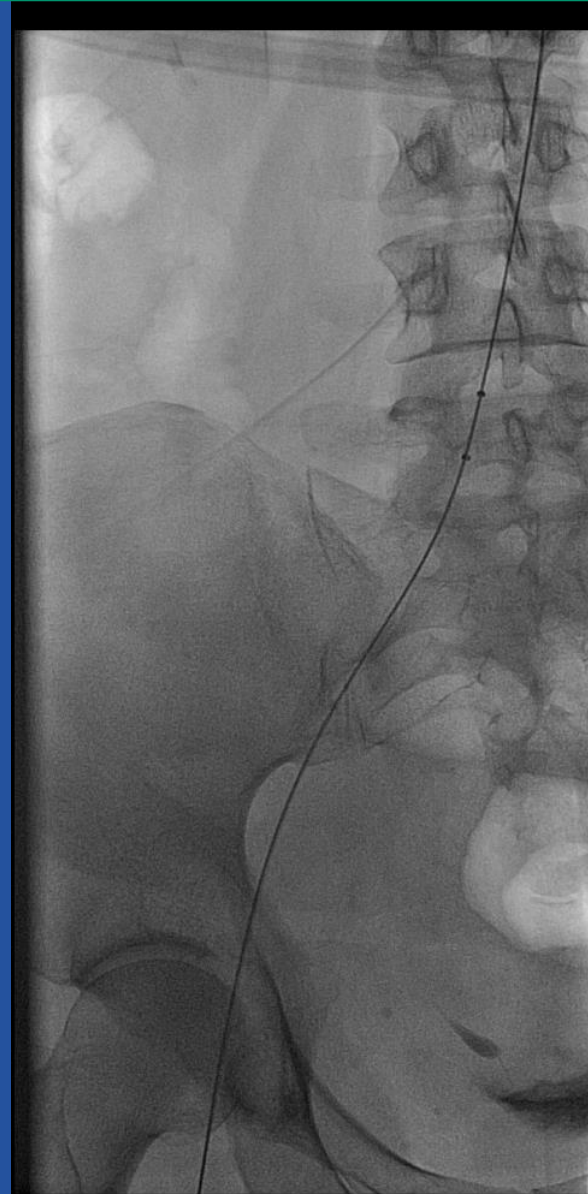
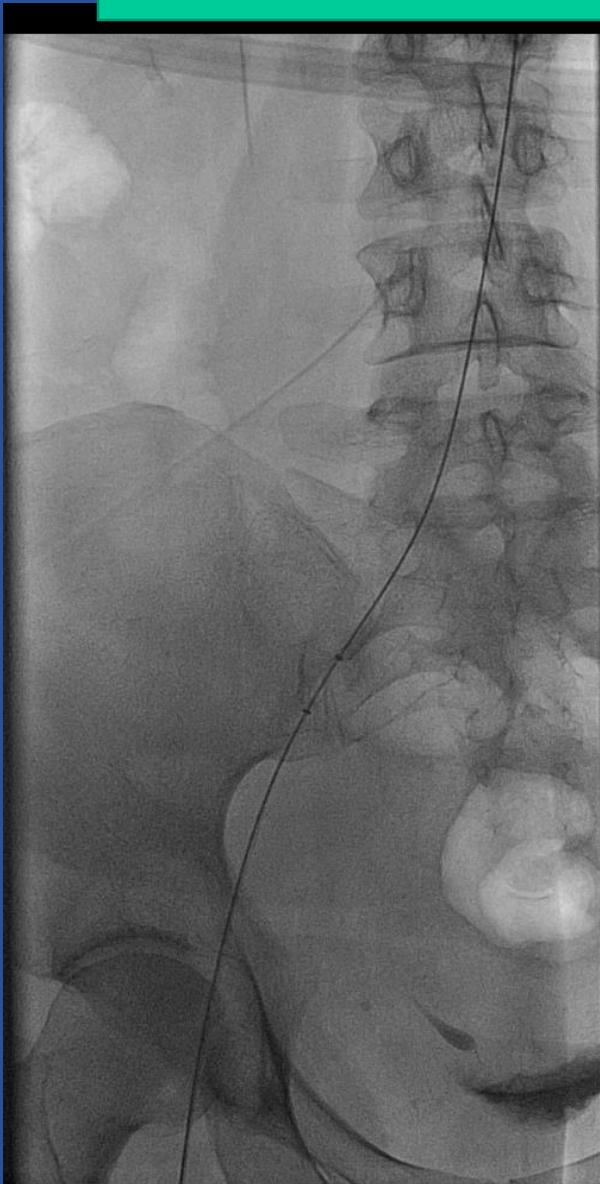- **Aspiration Catheters** in 4 sizes - CAT3,5,6 & 8
  - Design and materials used are meant to withstand vacuum pressure and will not collapse
- **Max Pump** provides -29 mmHg of continuous vacuum
- **Proprietary separator technology** to clean the catheter lumen for continuous aspiration

INDIGO® SYSTEM

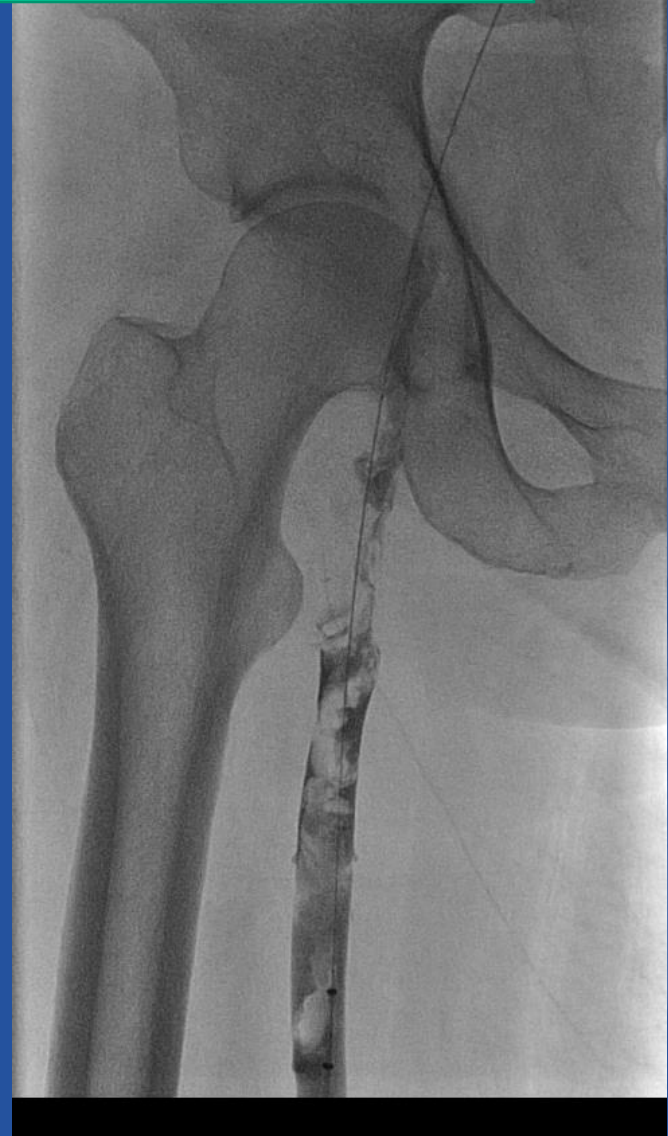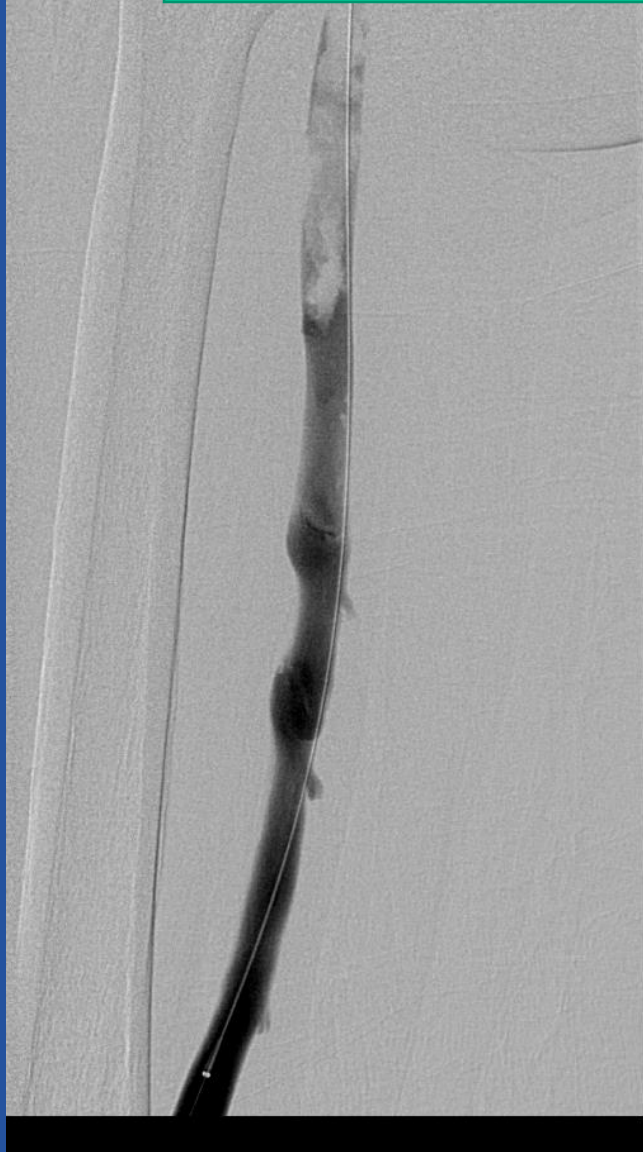
Angiojet power pulse 10 mg TPA in 100 cc of saline

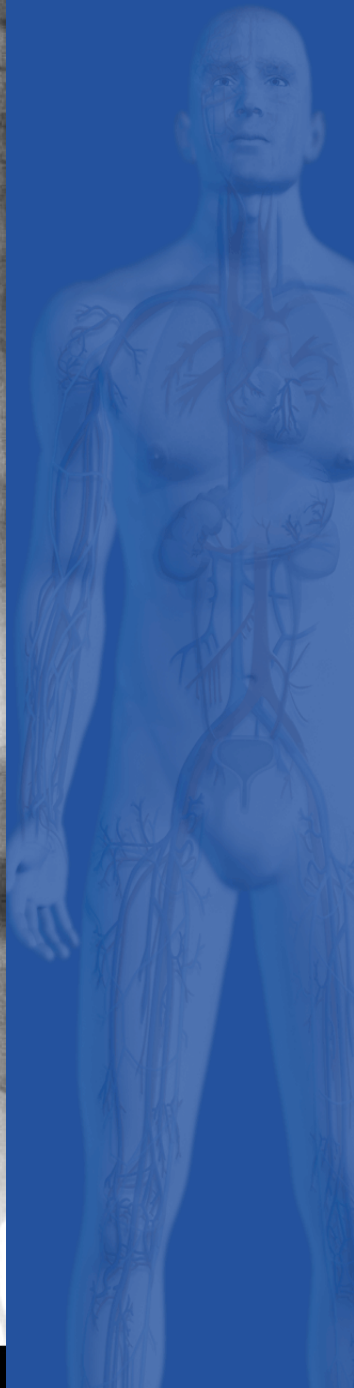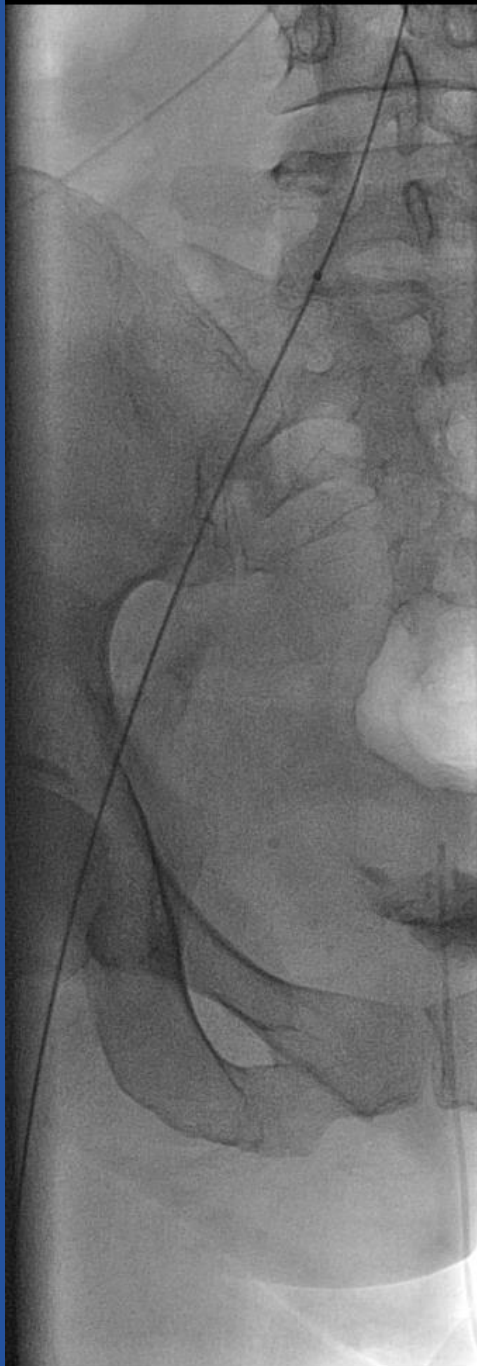

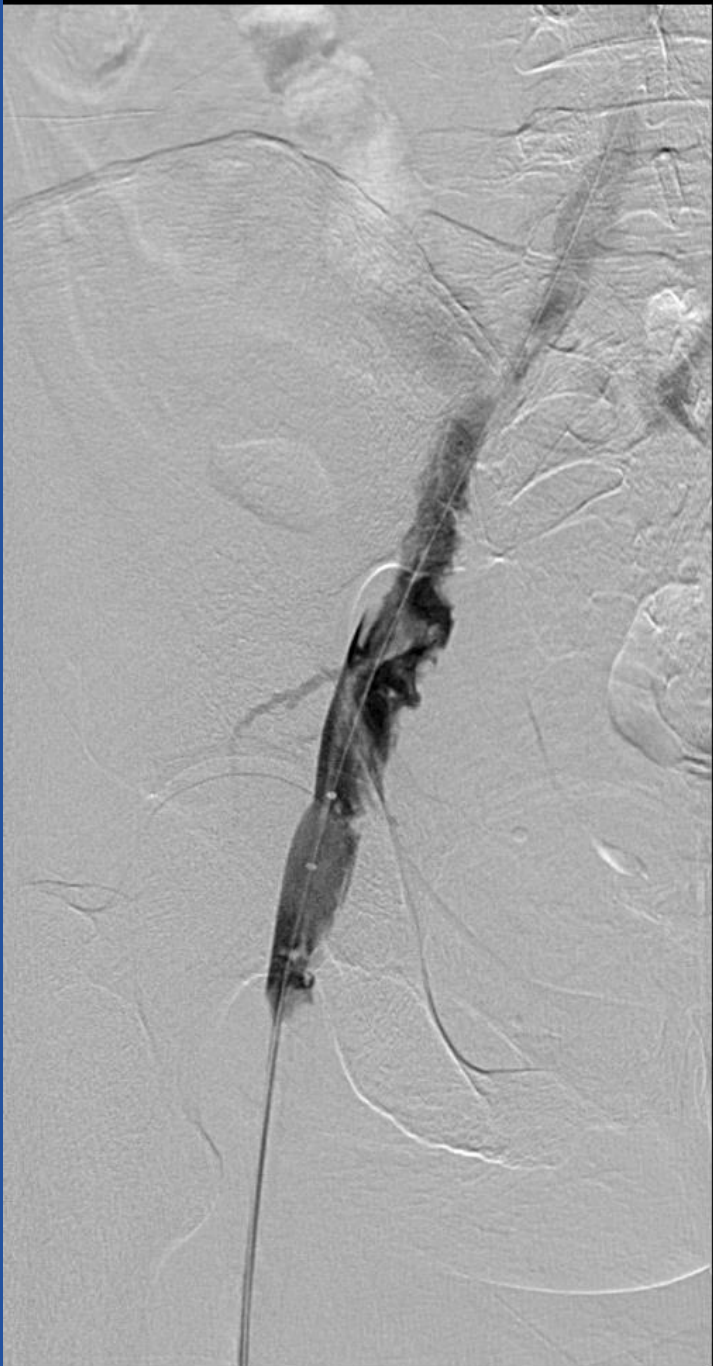
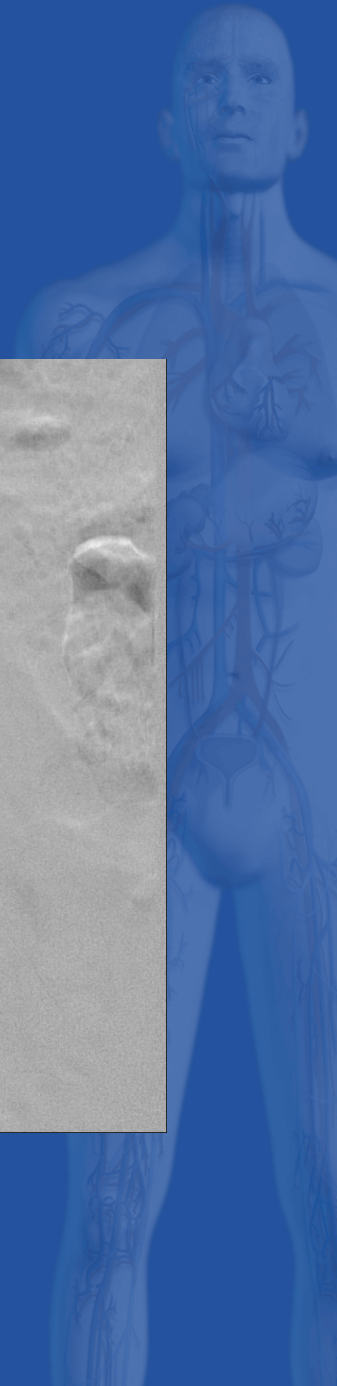
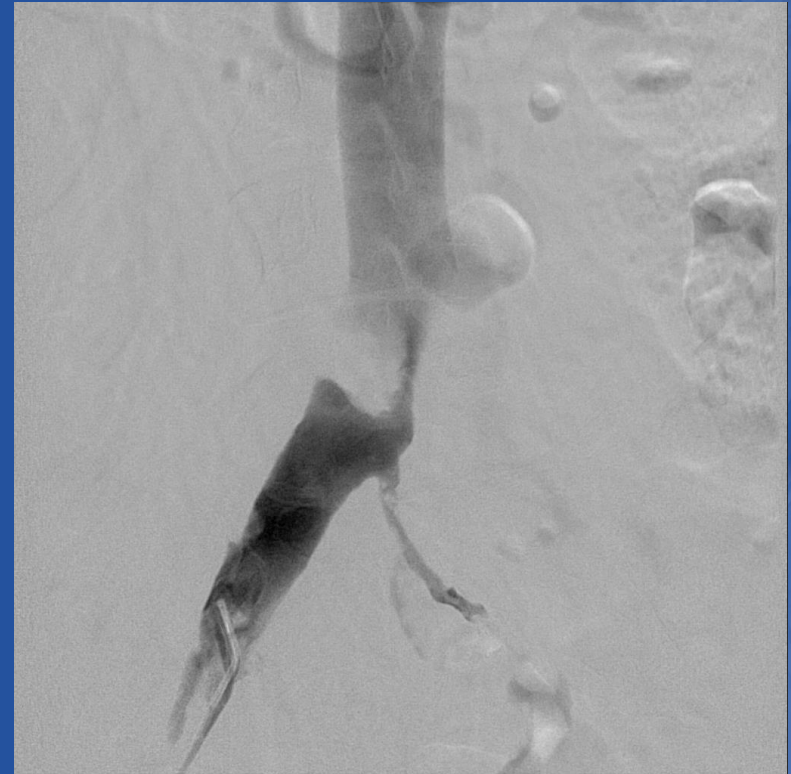
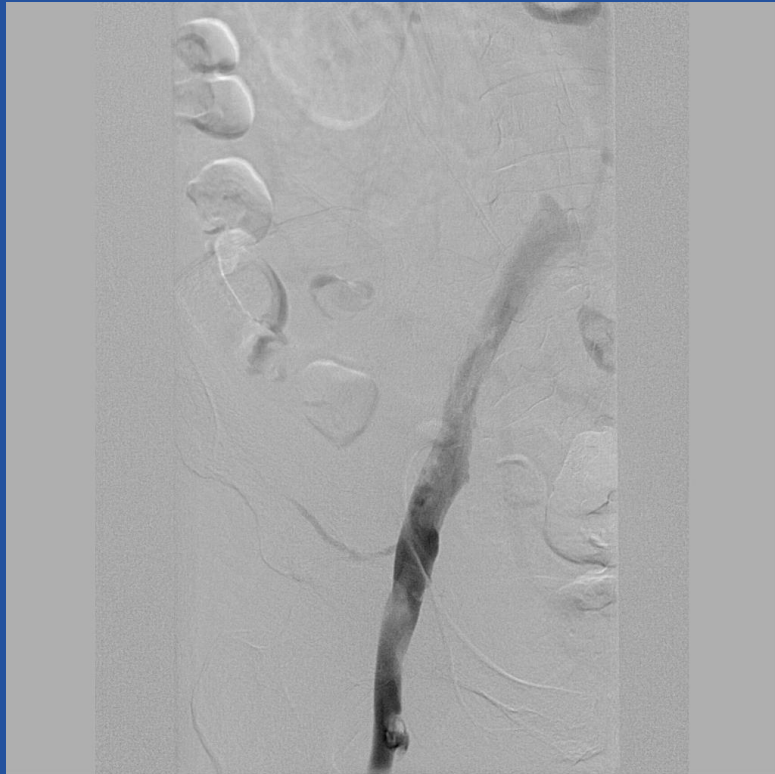
Dwell for 40 to 45 min to macerate the thrombus

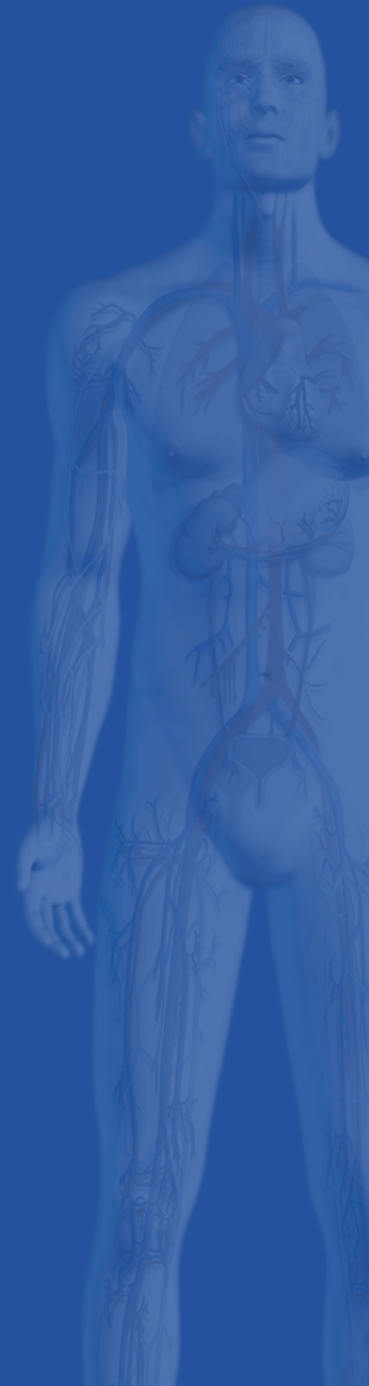
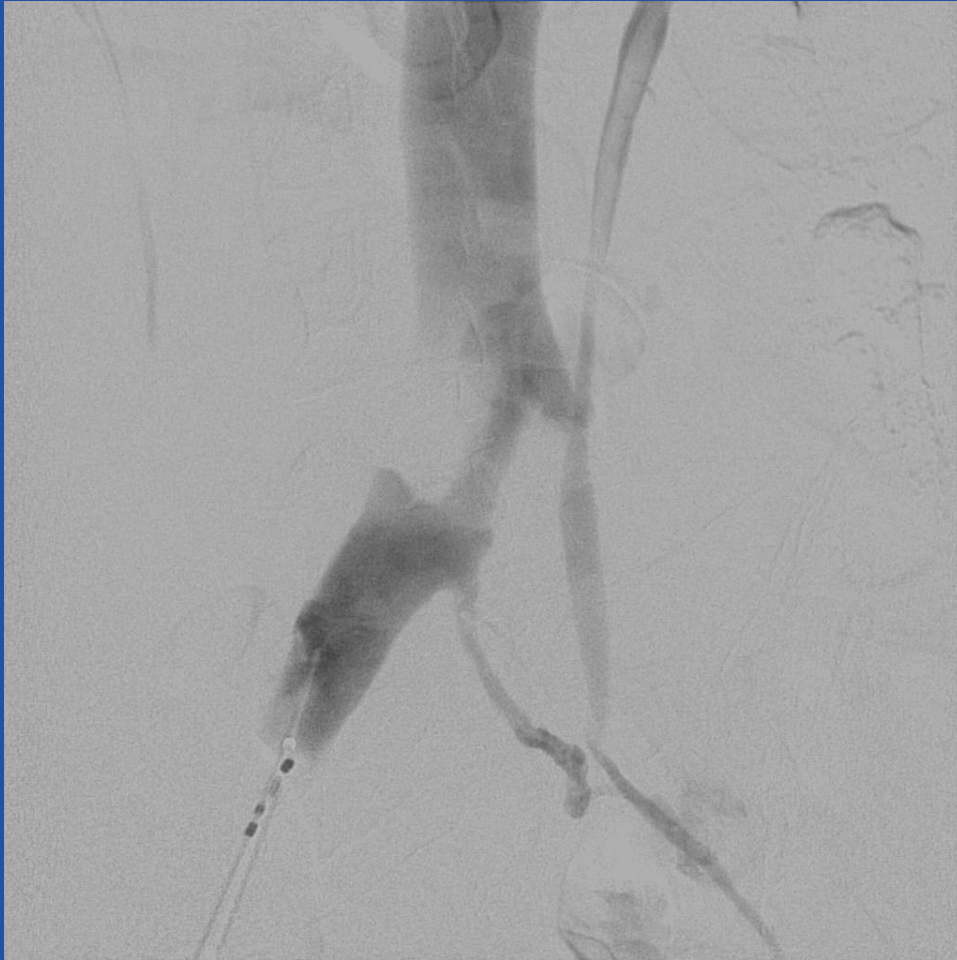

**Activate the Angiojet to remove thrombus from proximal iliac to popliteal vein**

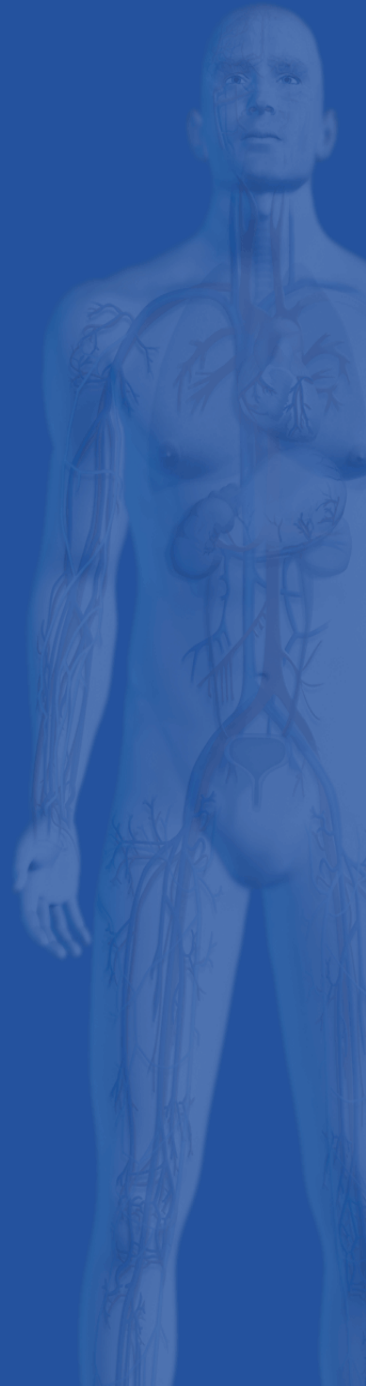
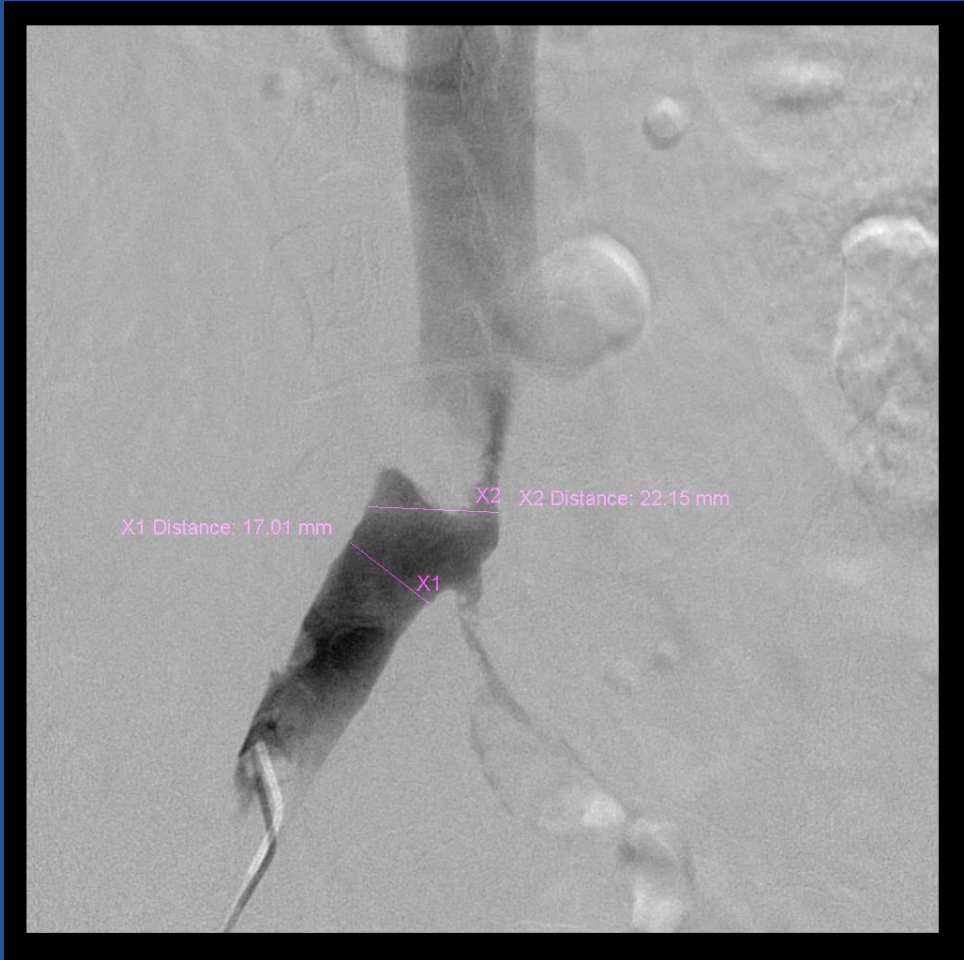

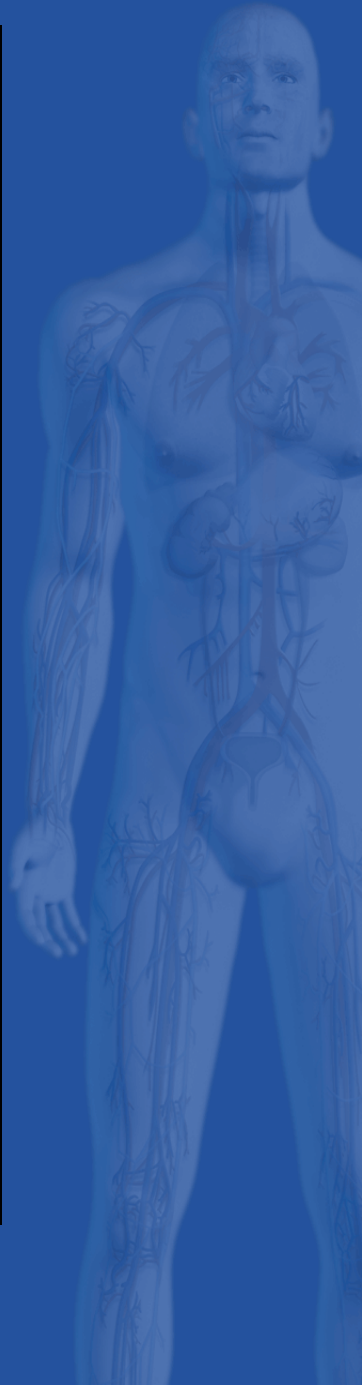
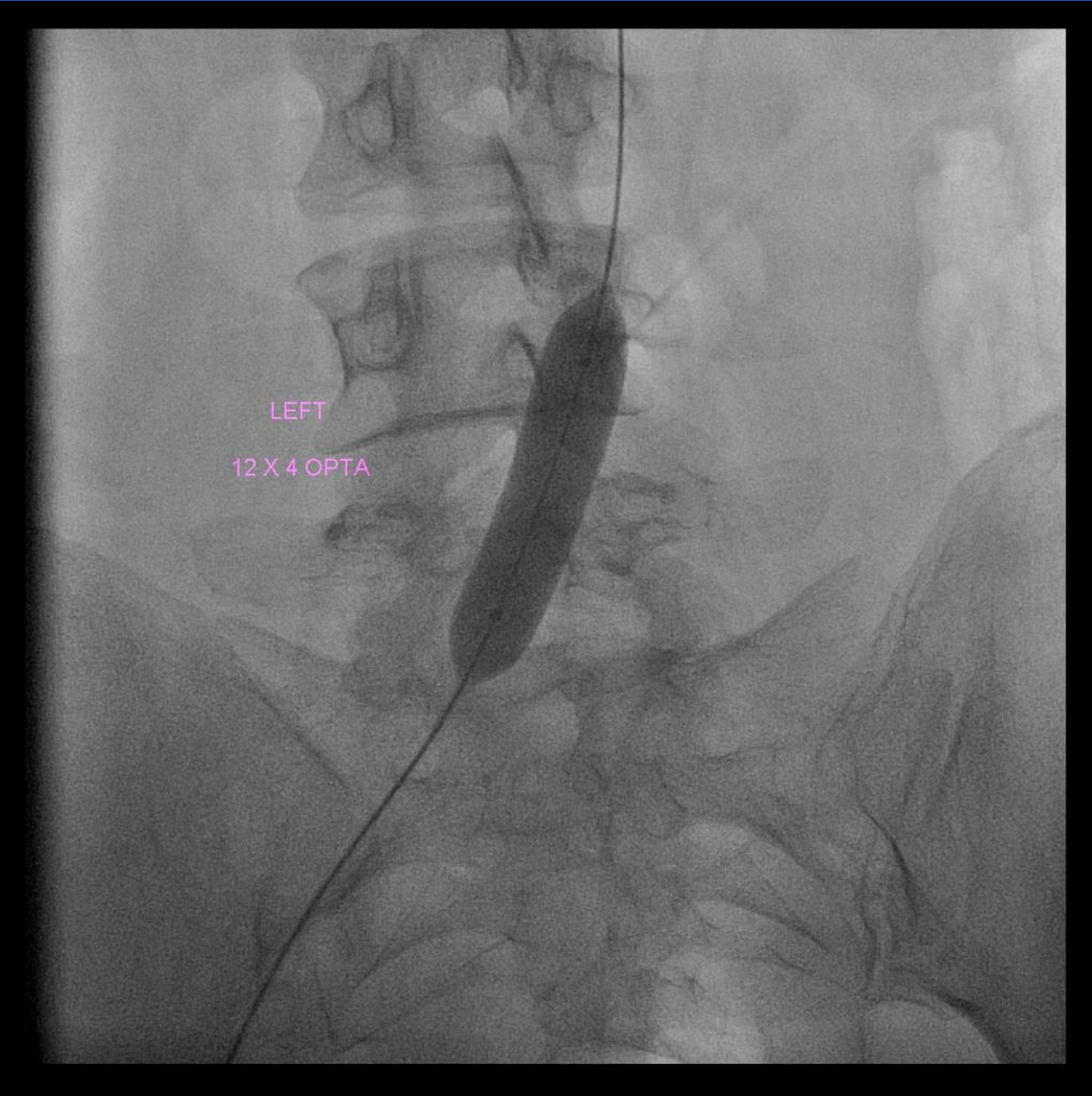



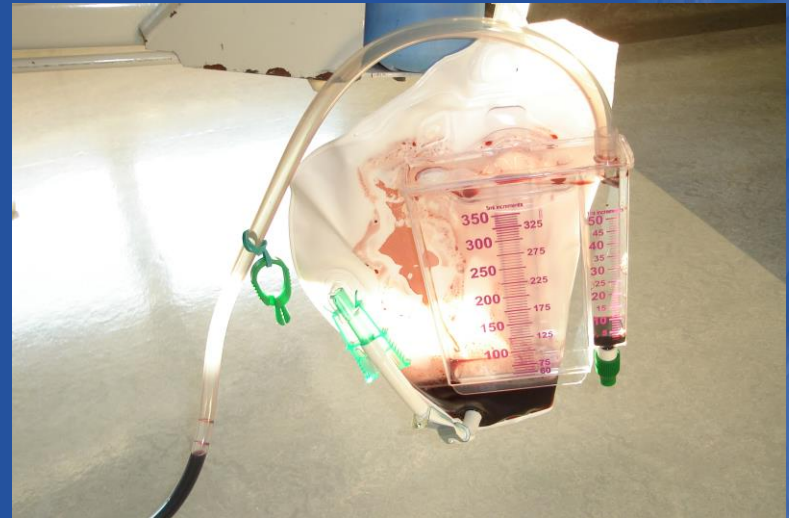
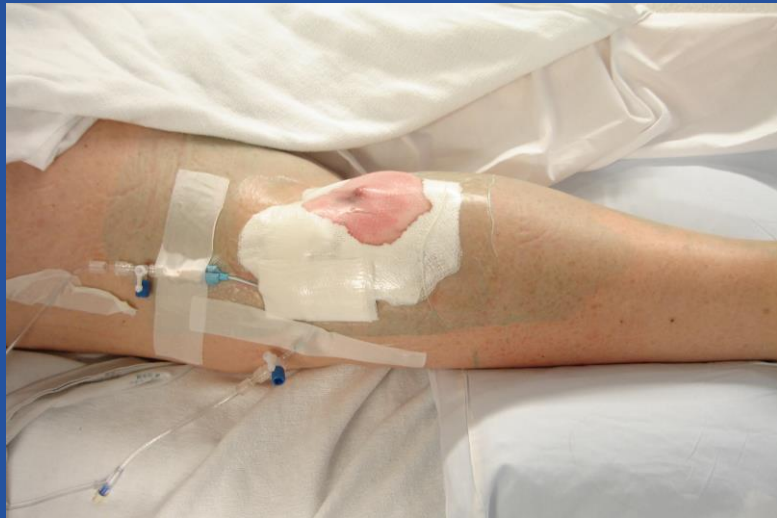

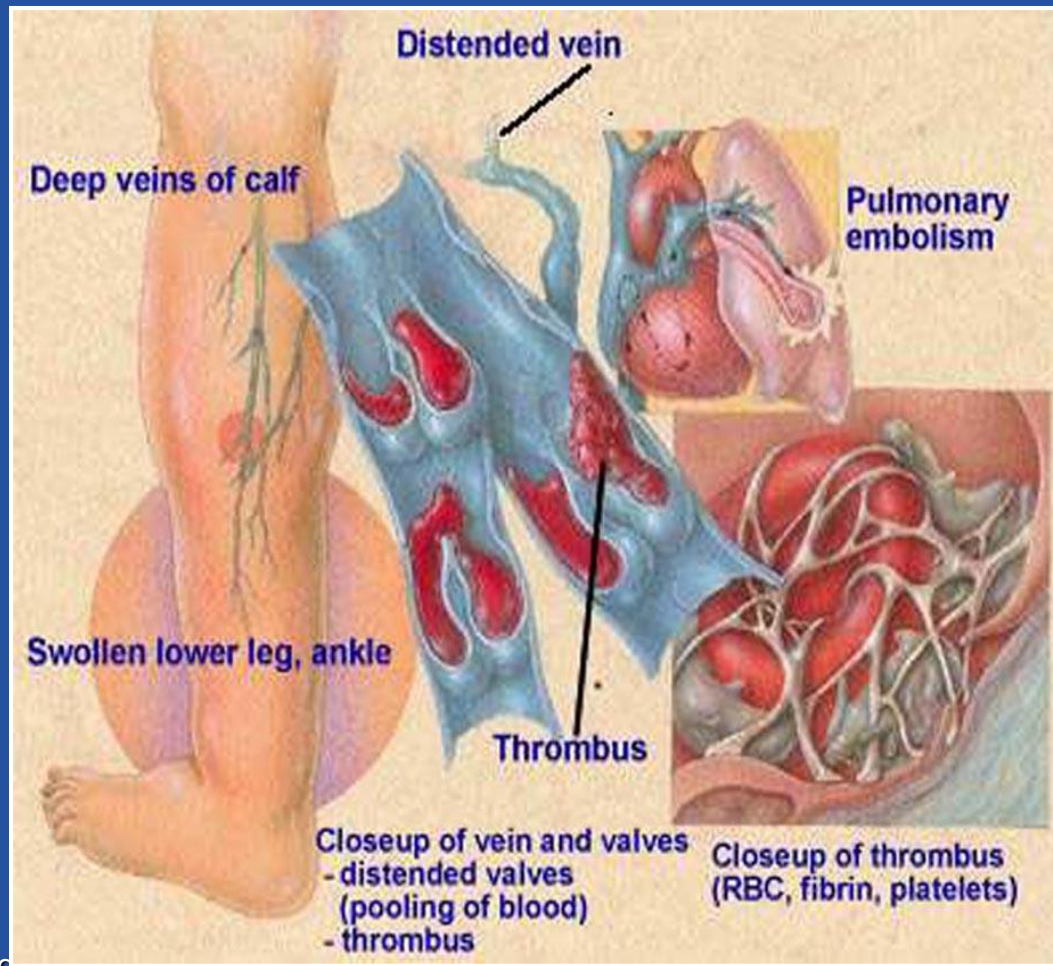






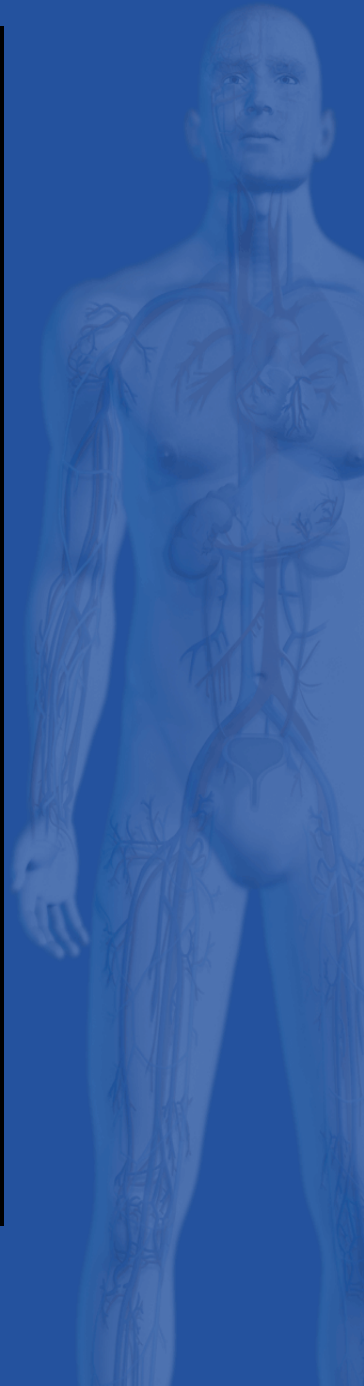
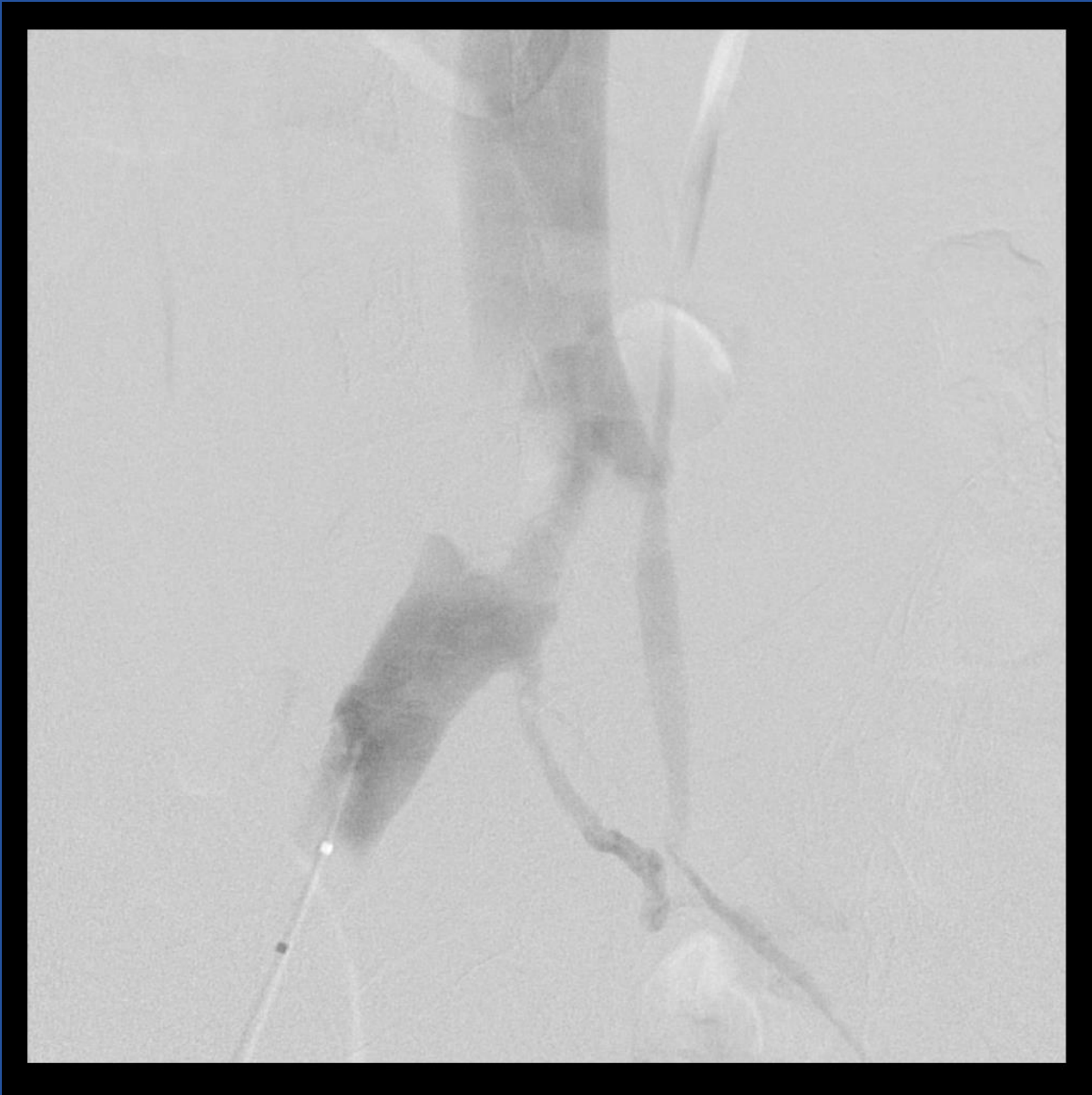


# Pathophysiology



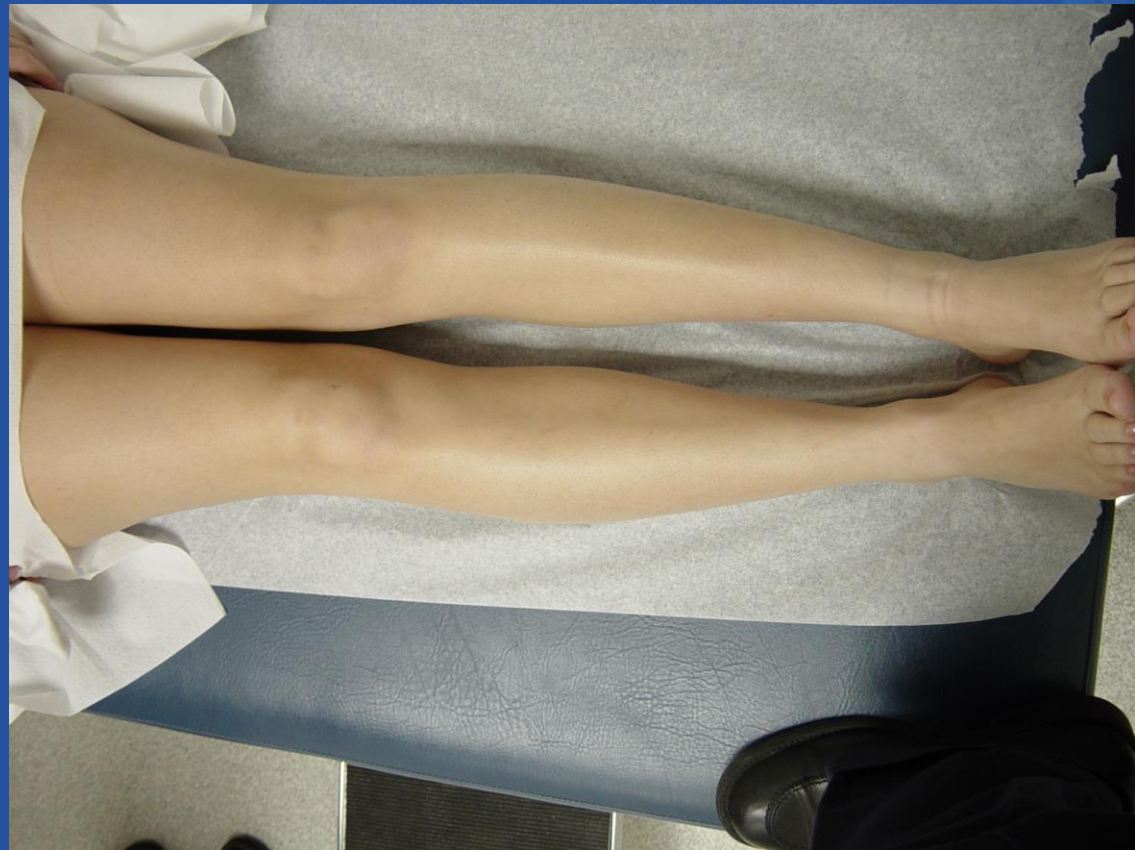<http://www.uspharmacist.com/newlook/06/deepvein/06.htm>. Accessed February 2009.

Originally published in *US Pharmacist* with permission of the artist Kevin A. Sommerville. May not be reproduced without permission of the artist.

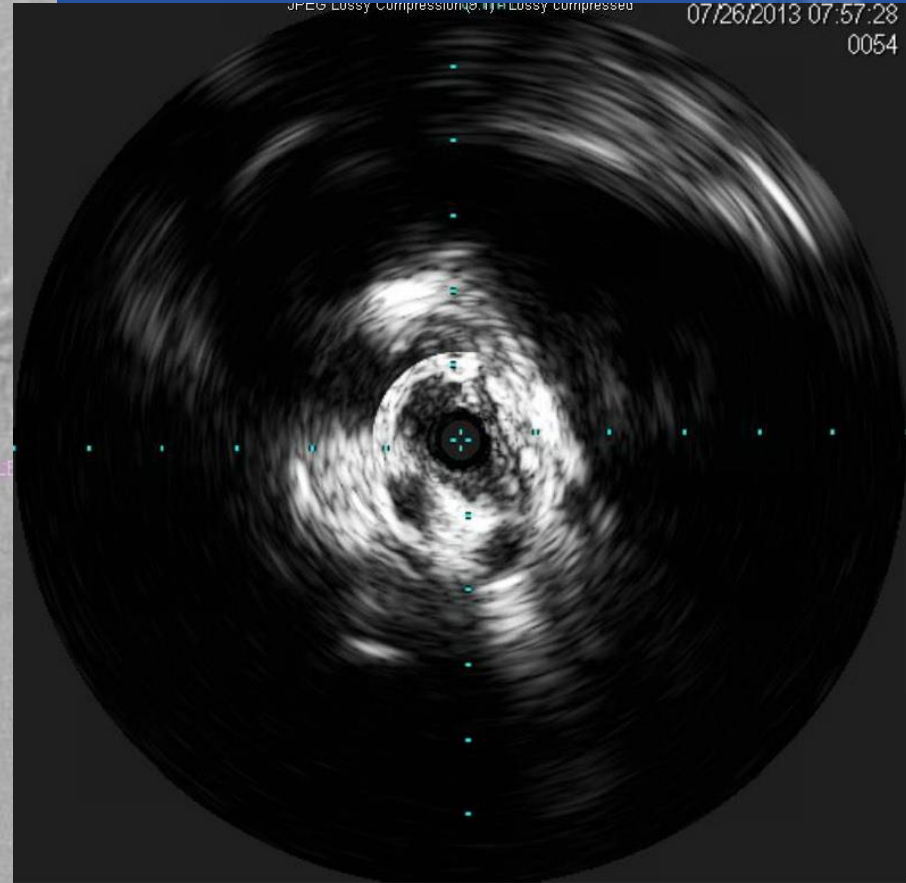
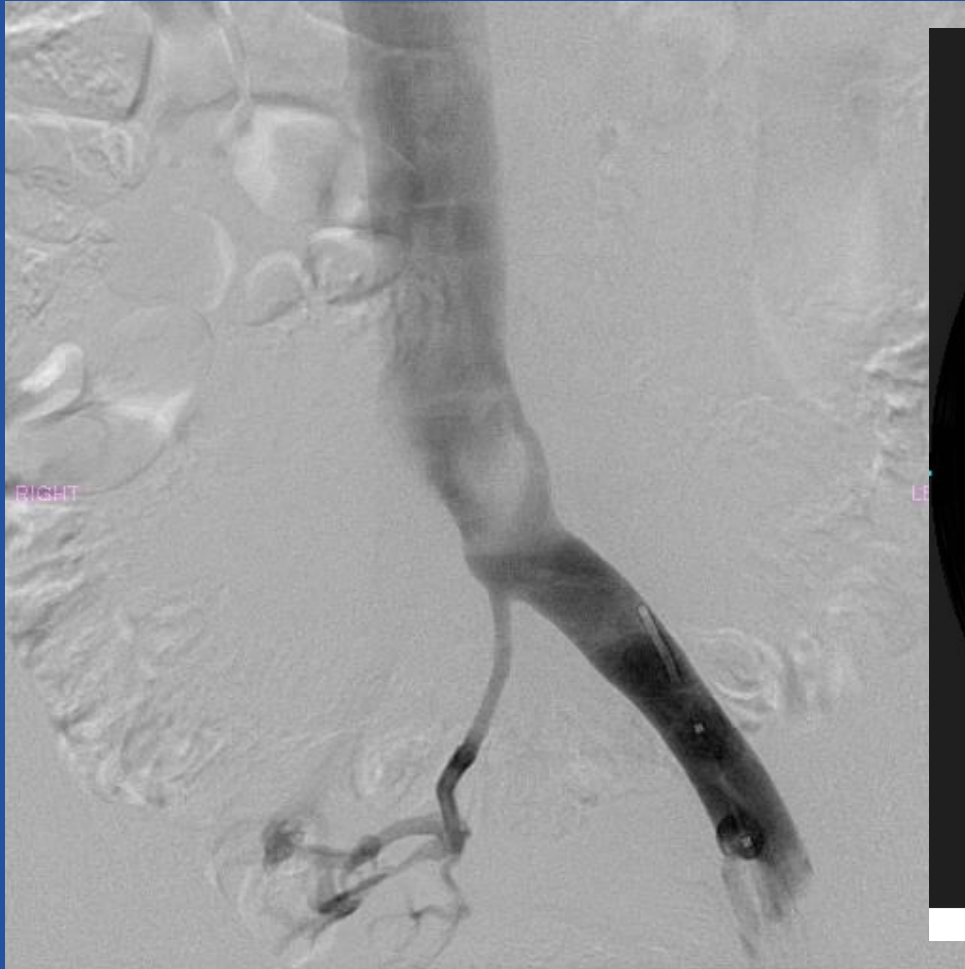


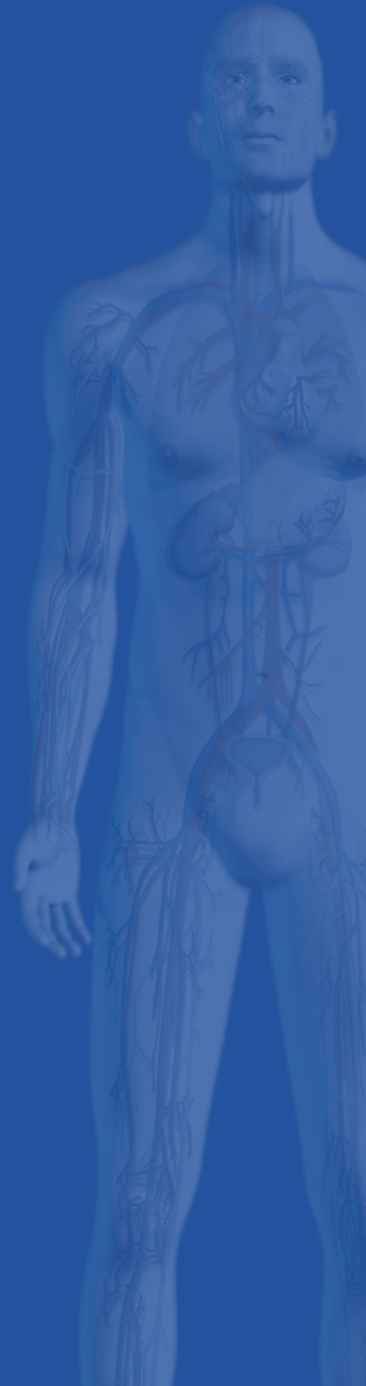
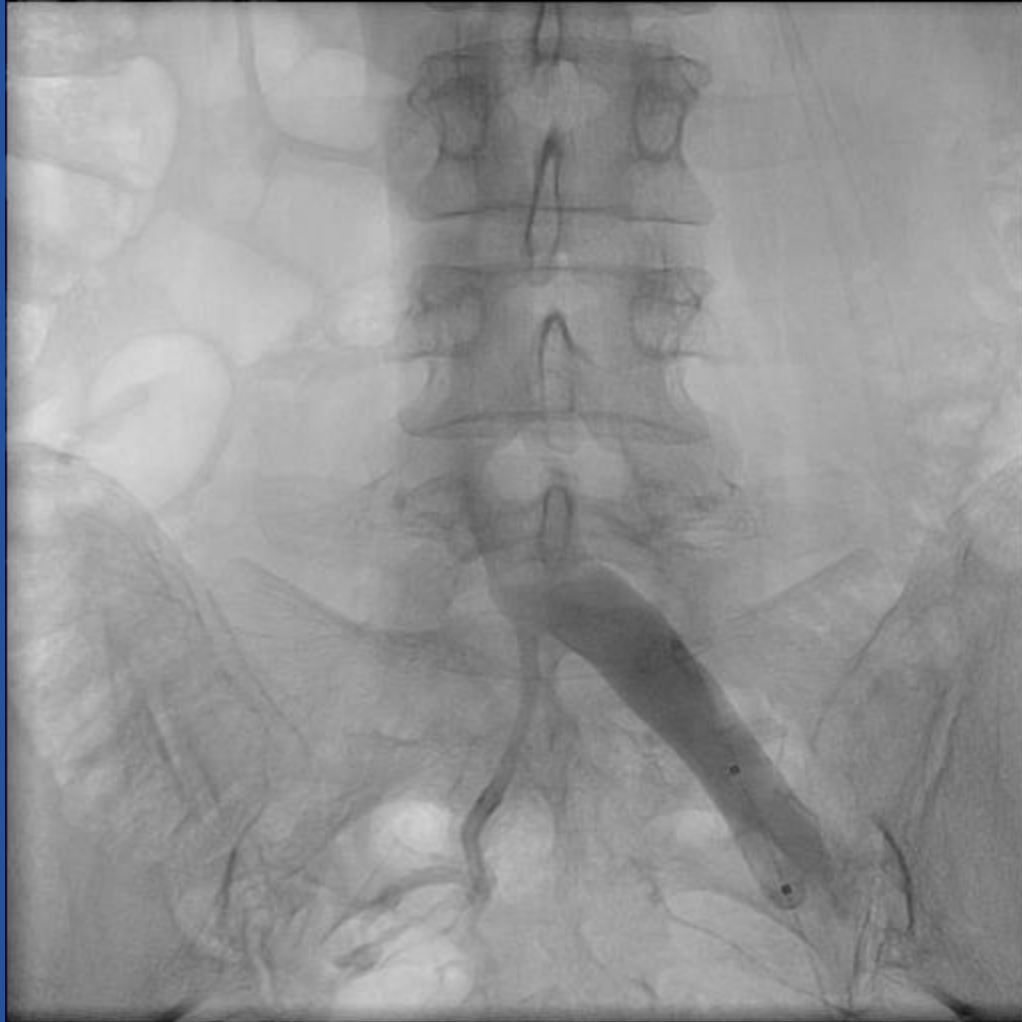**D/C home on Coumadin and ASA**

- Left leg swelling completely resolved
- Discharged on Coumadin and bay ASA

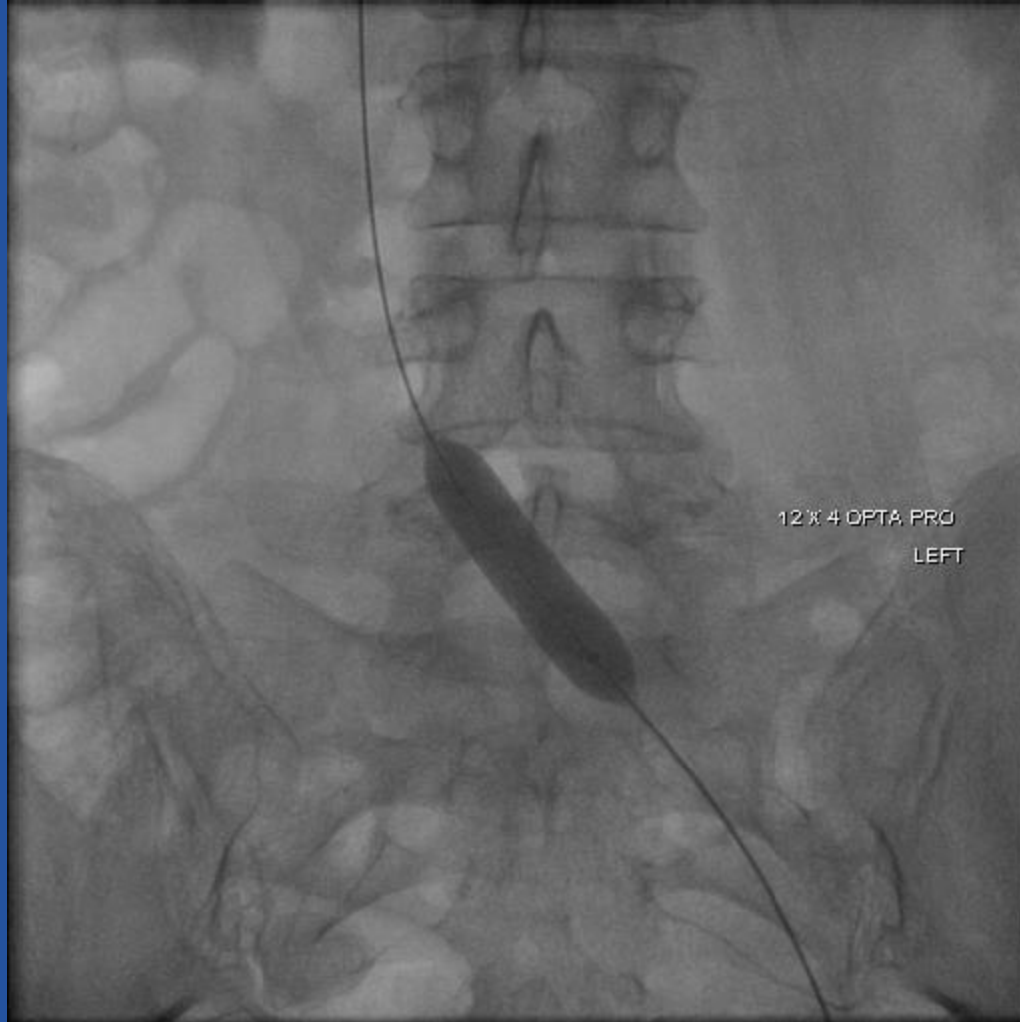


# Return 4 weeks after on Coumadin

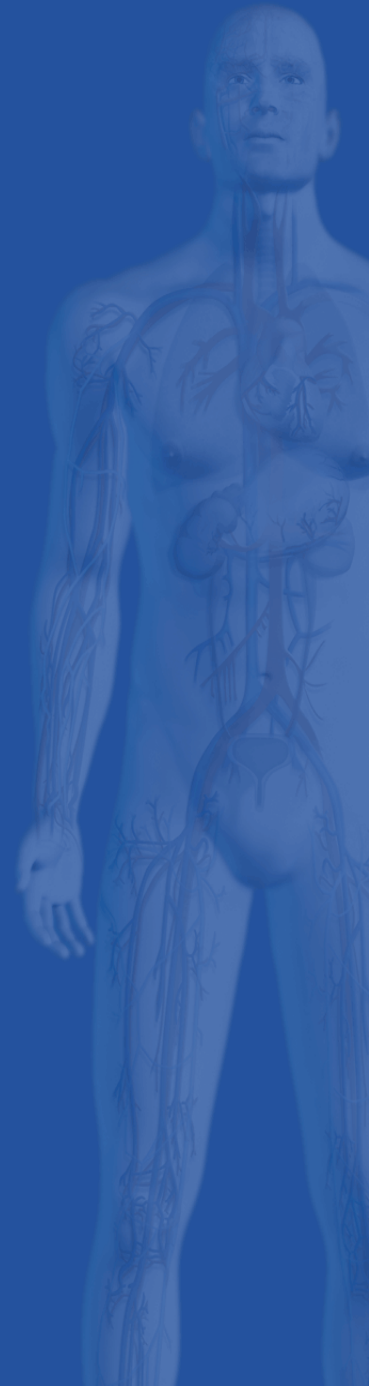


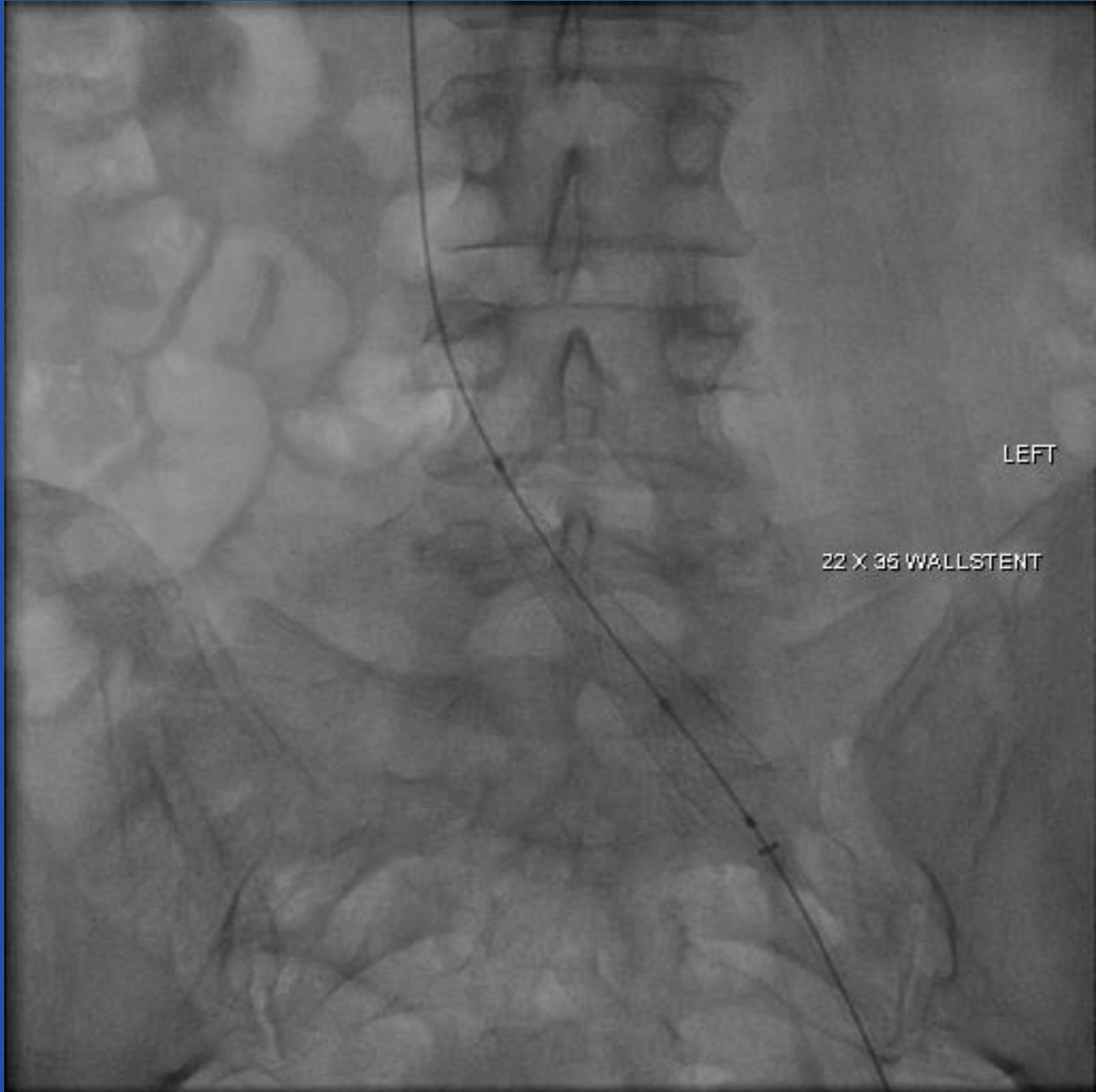






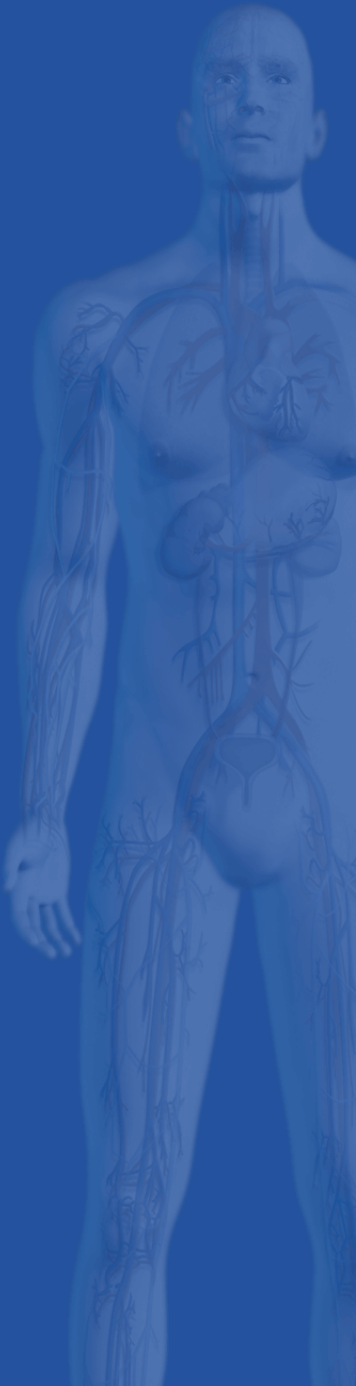
12 X 4 OPTA PRO  
LEFT

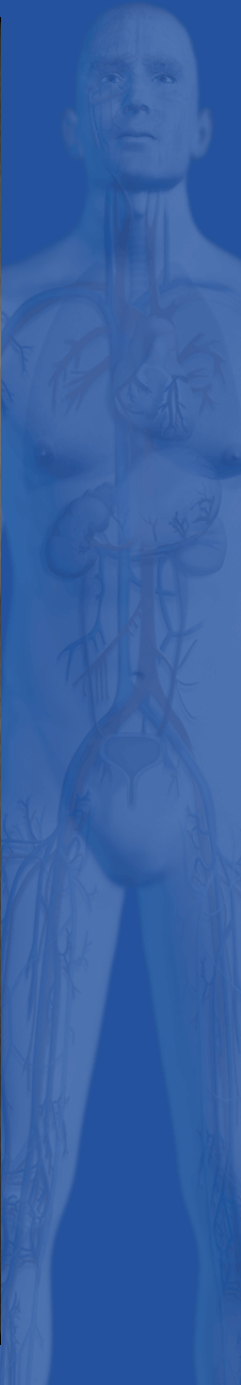
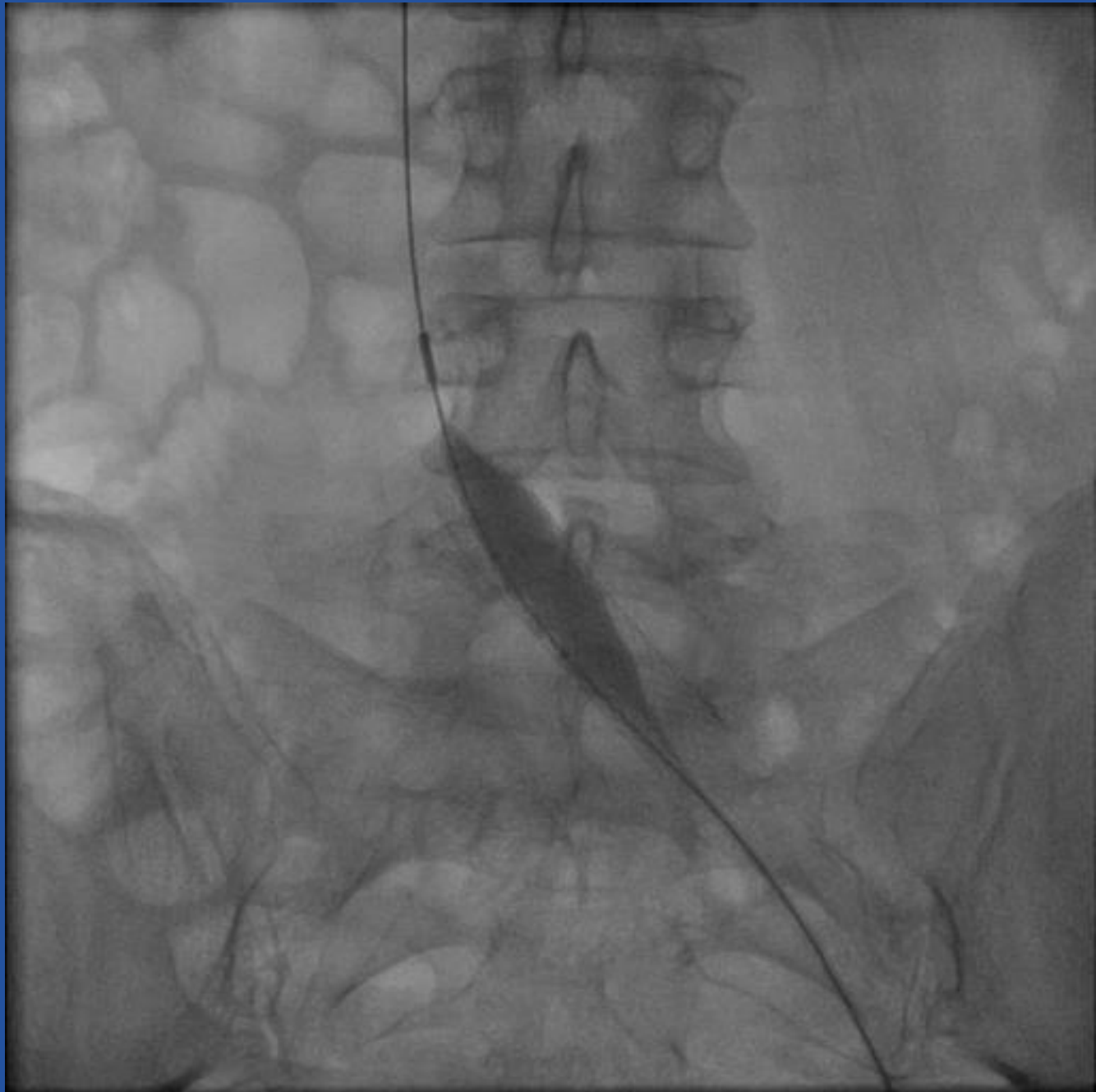

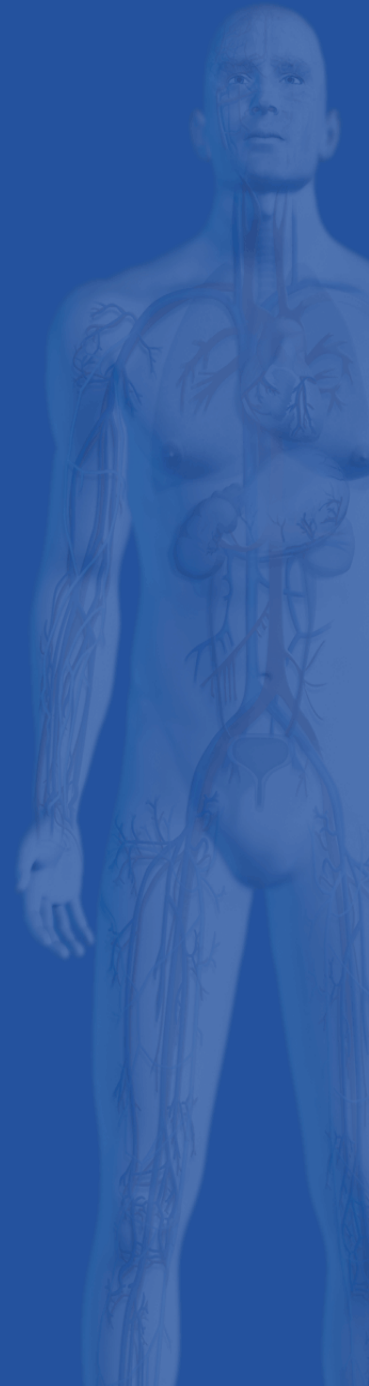
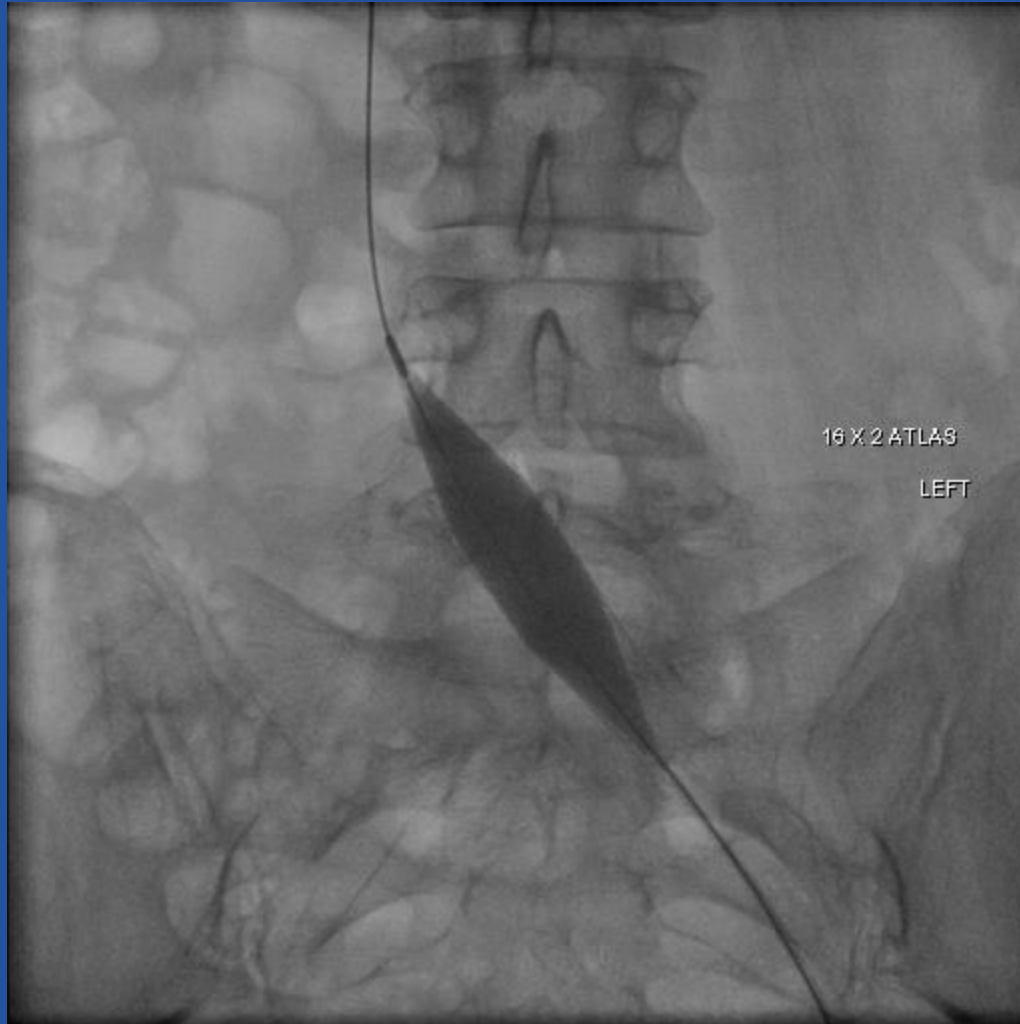


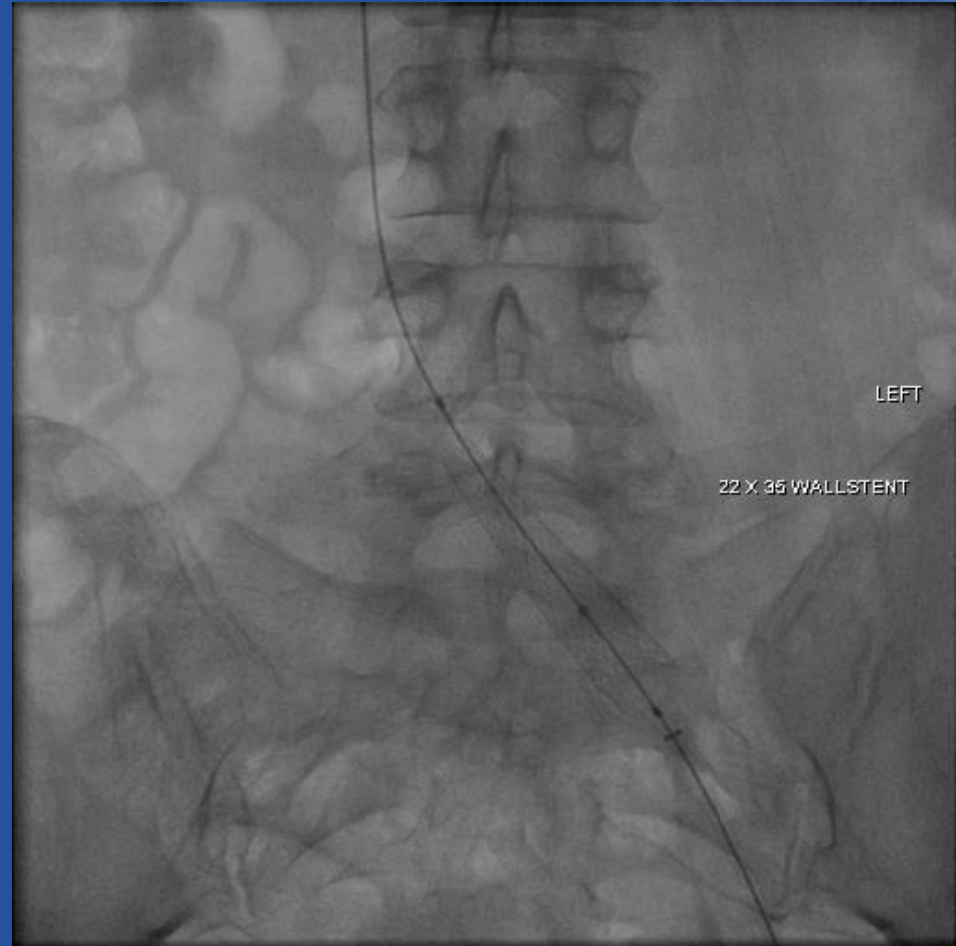
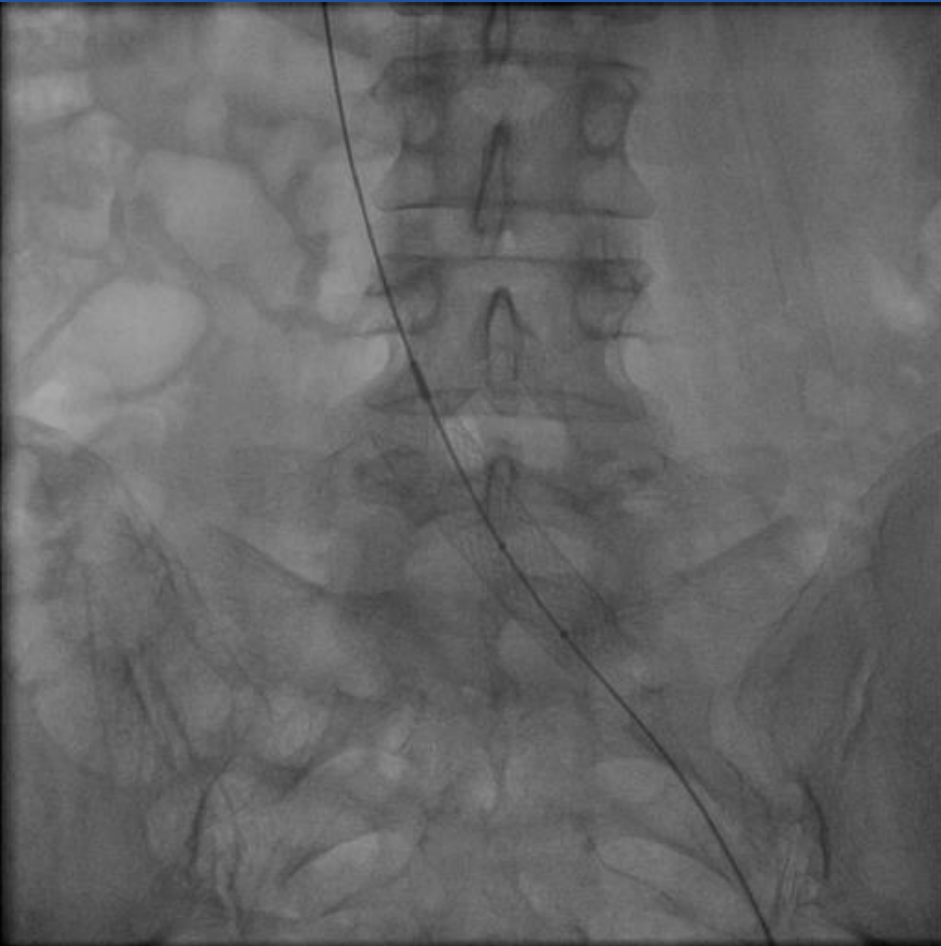LEFT

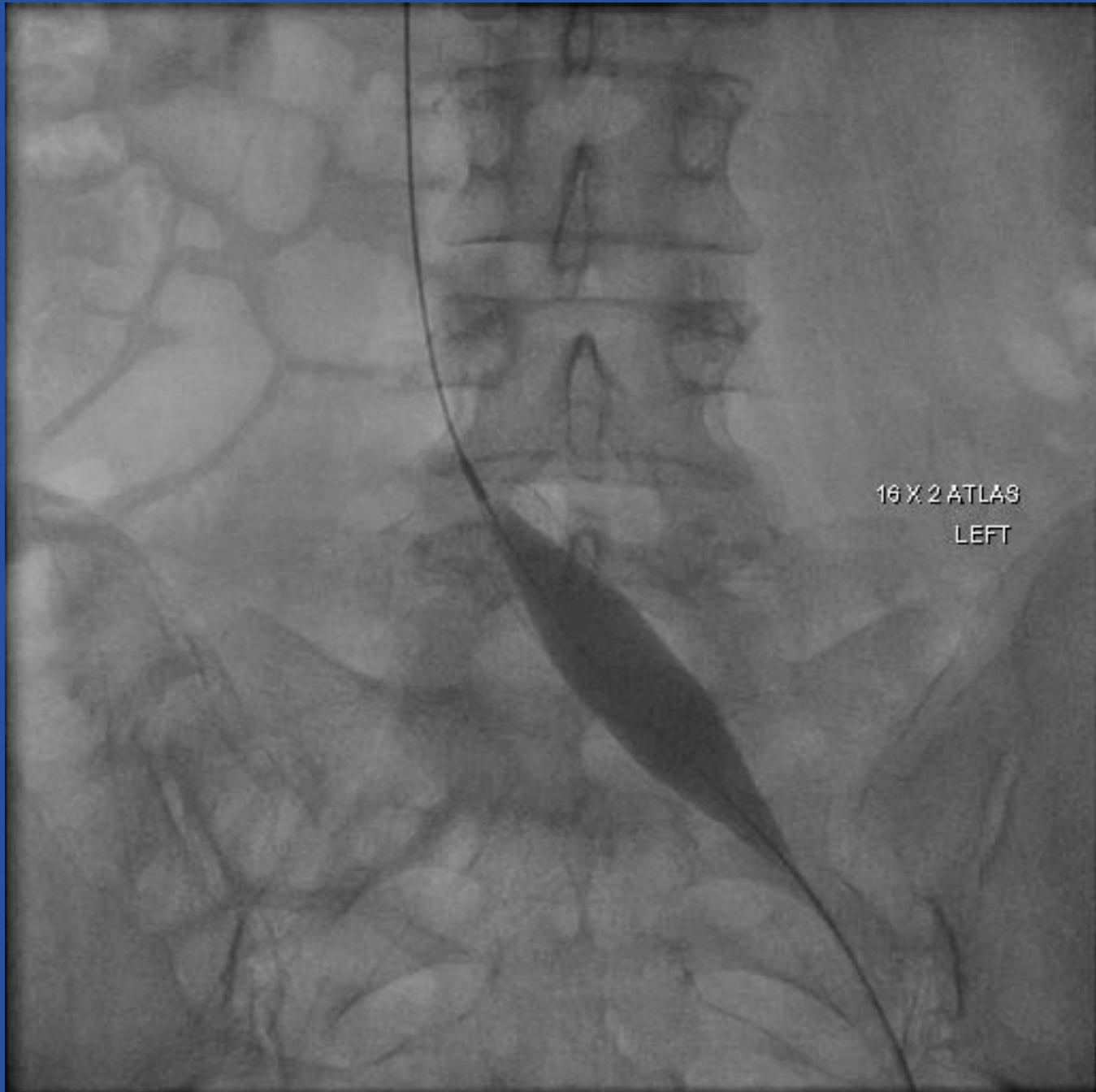22 X 35 WALLSTENT






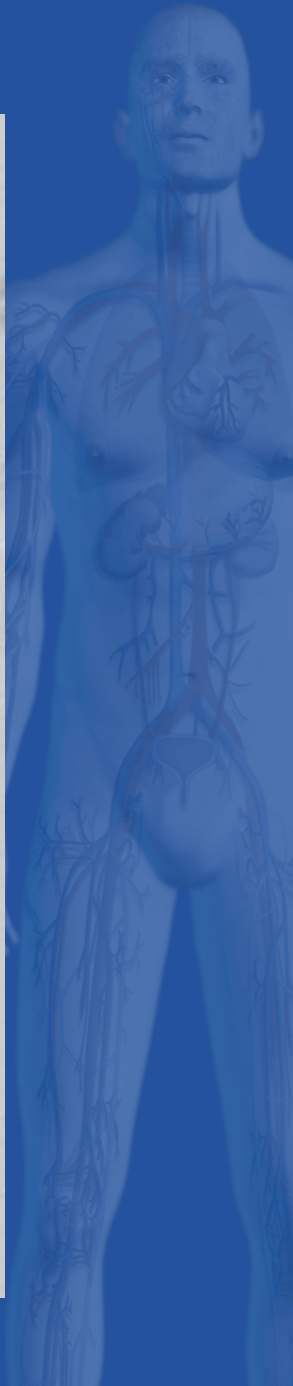
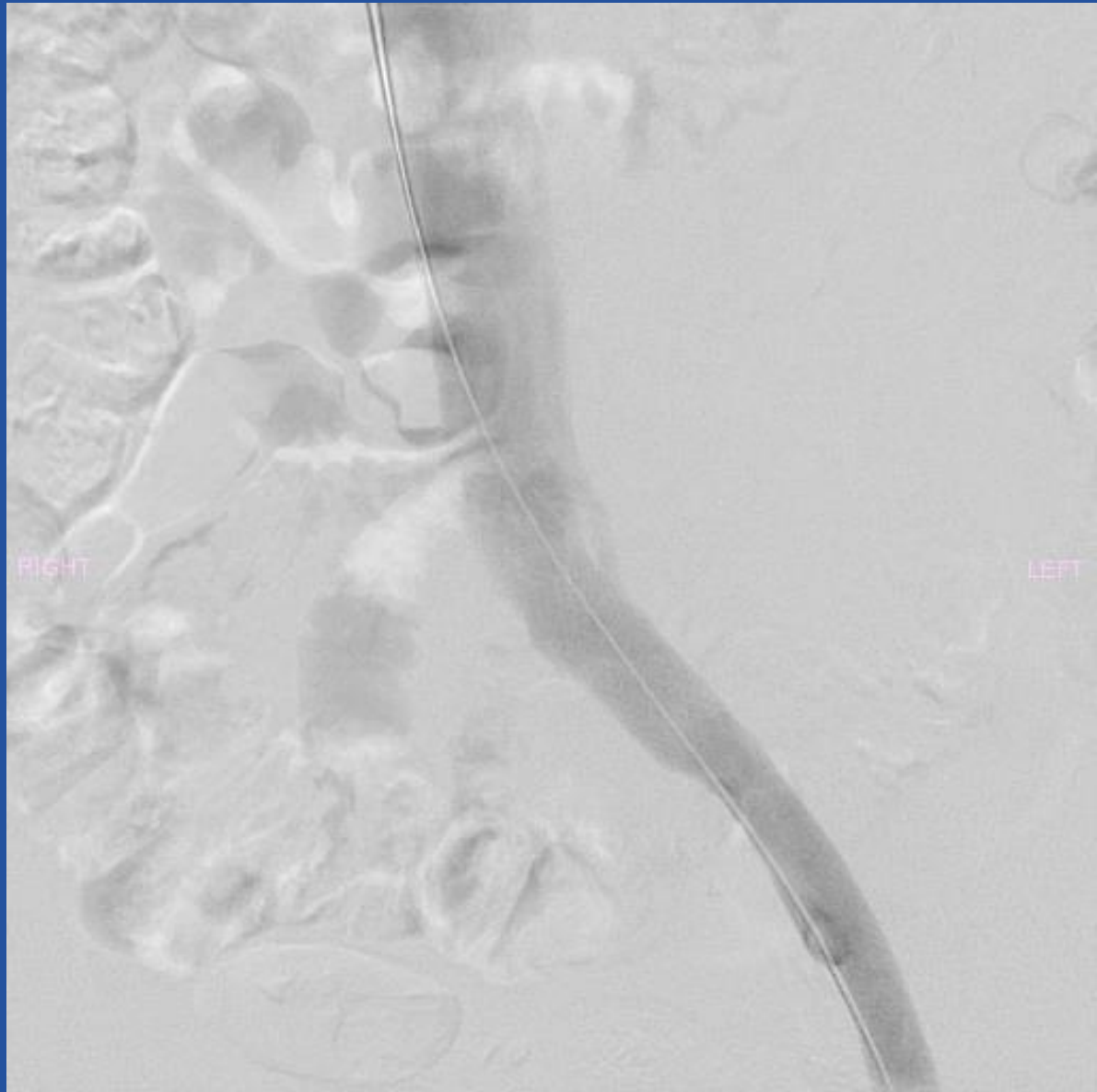

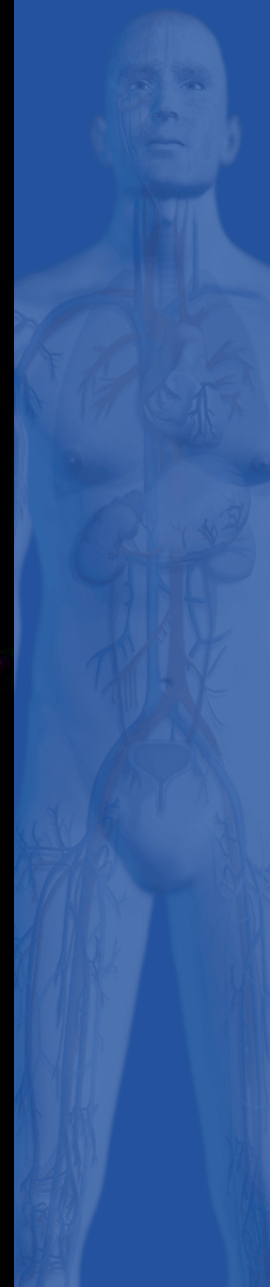
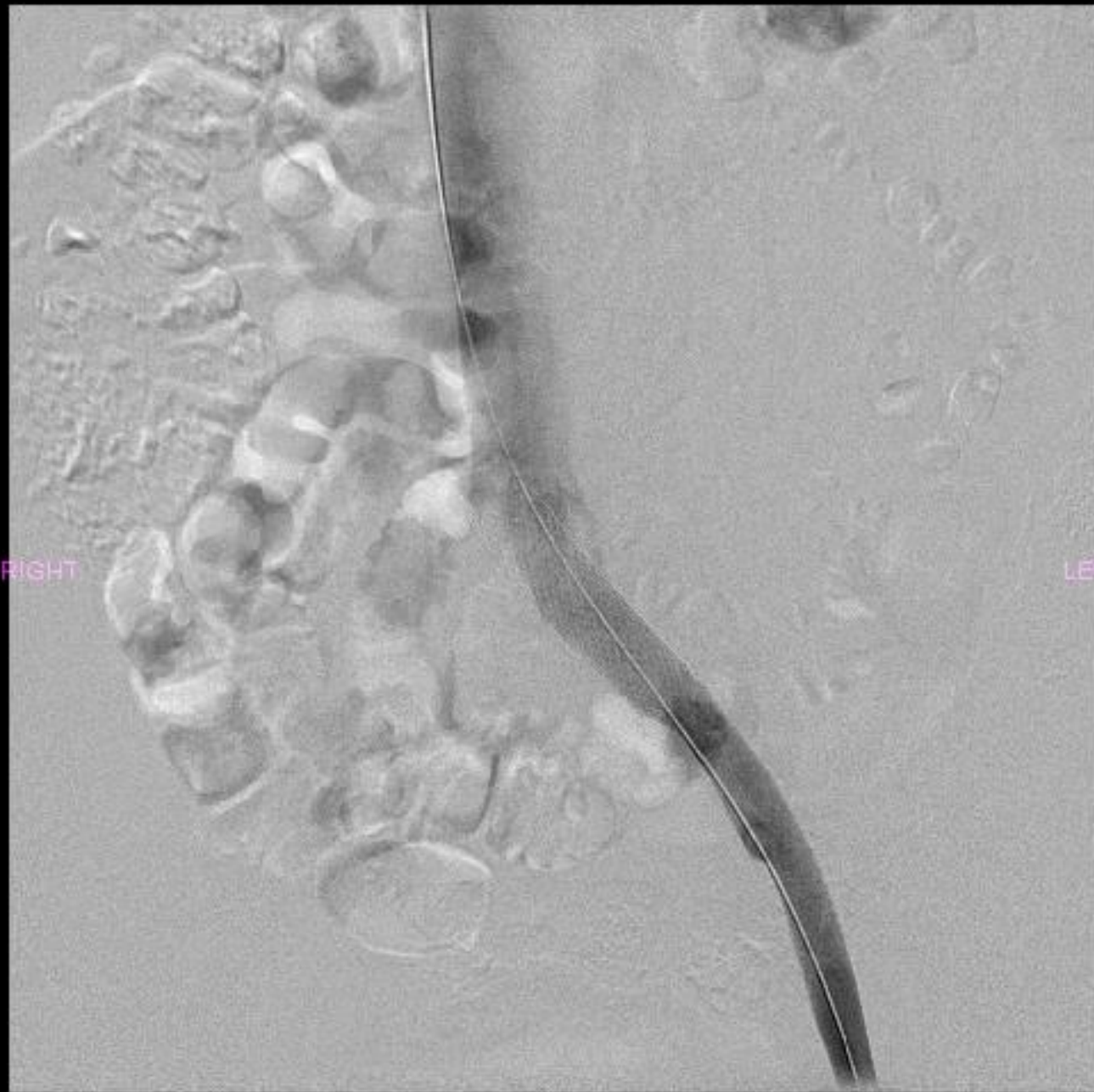



16 X 2 ATLAS  
LEFT

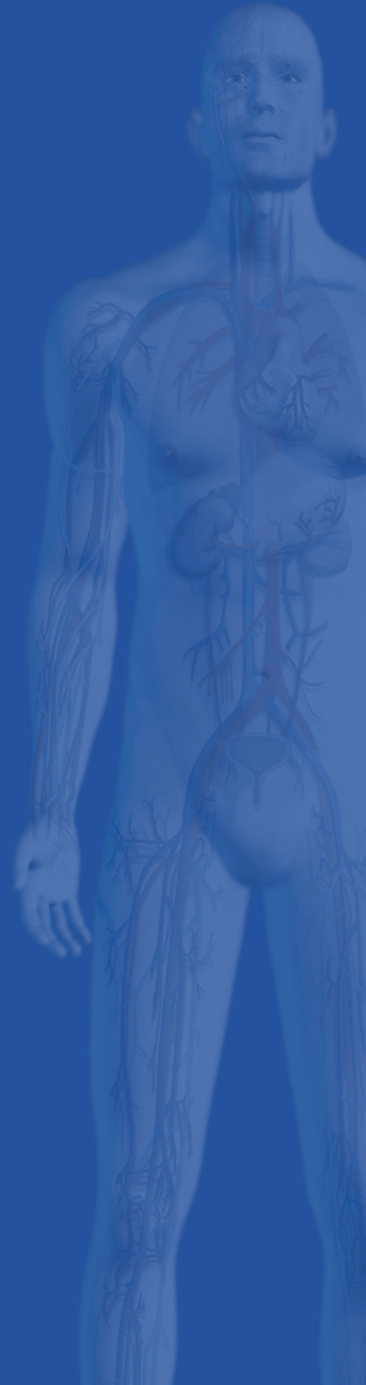




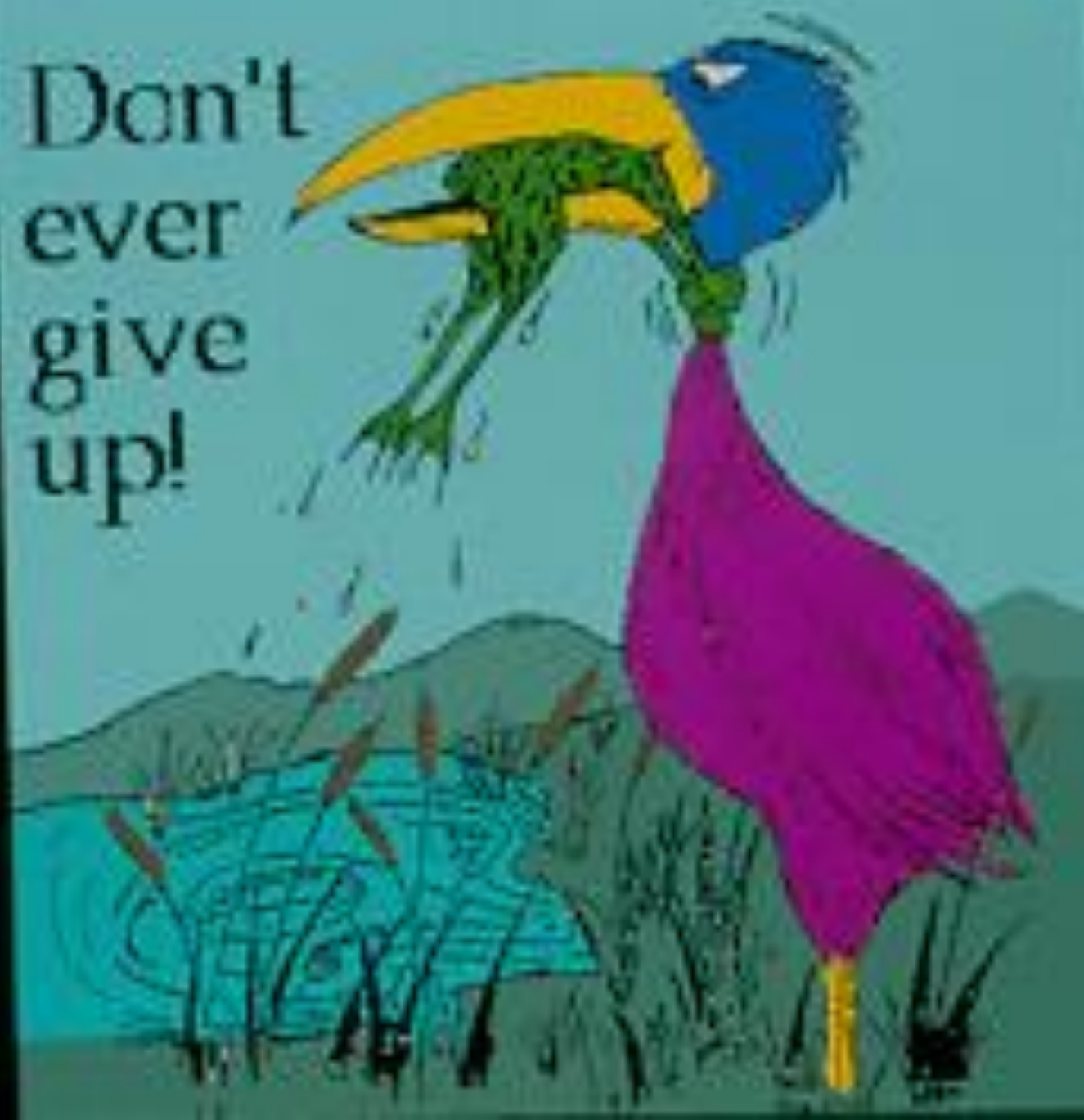



- Discharge on Coumadin and baby ASA

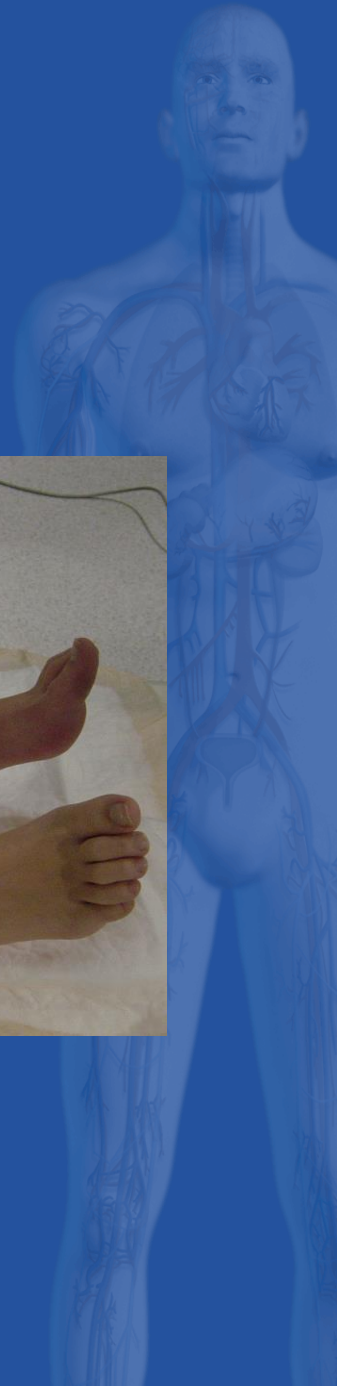
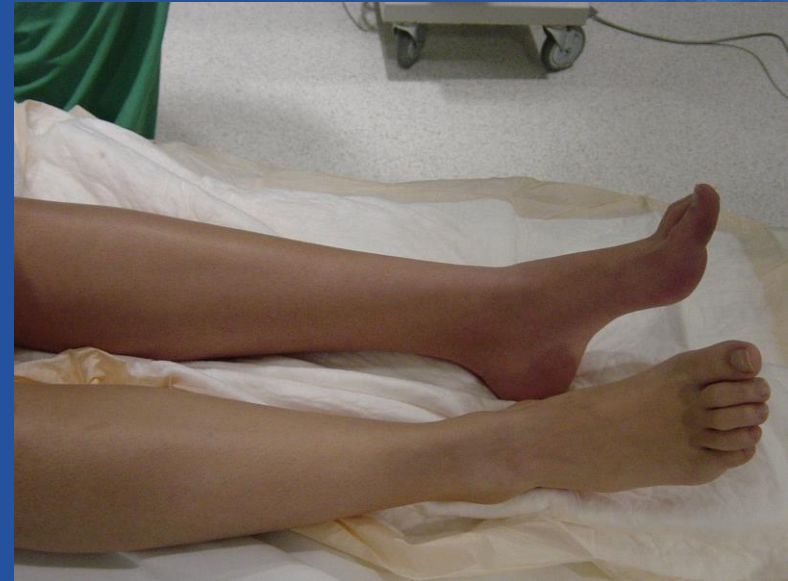
Don't  
ever  
give  
up!

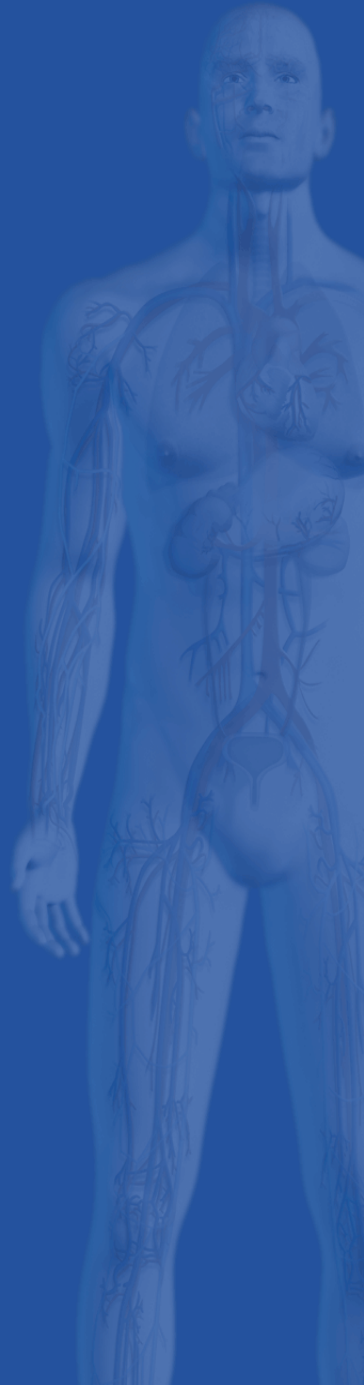


# Left Ilio-Femoral DVT

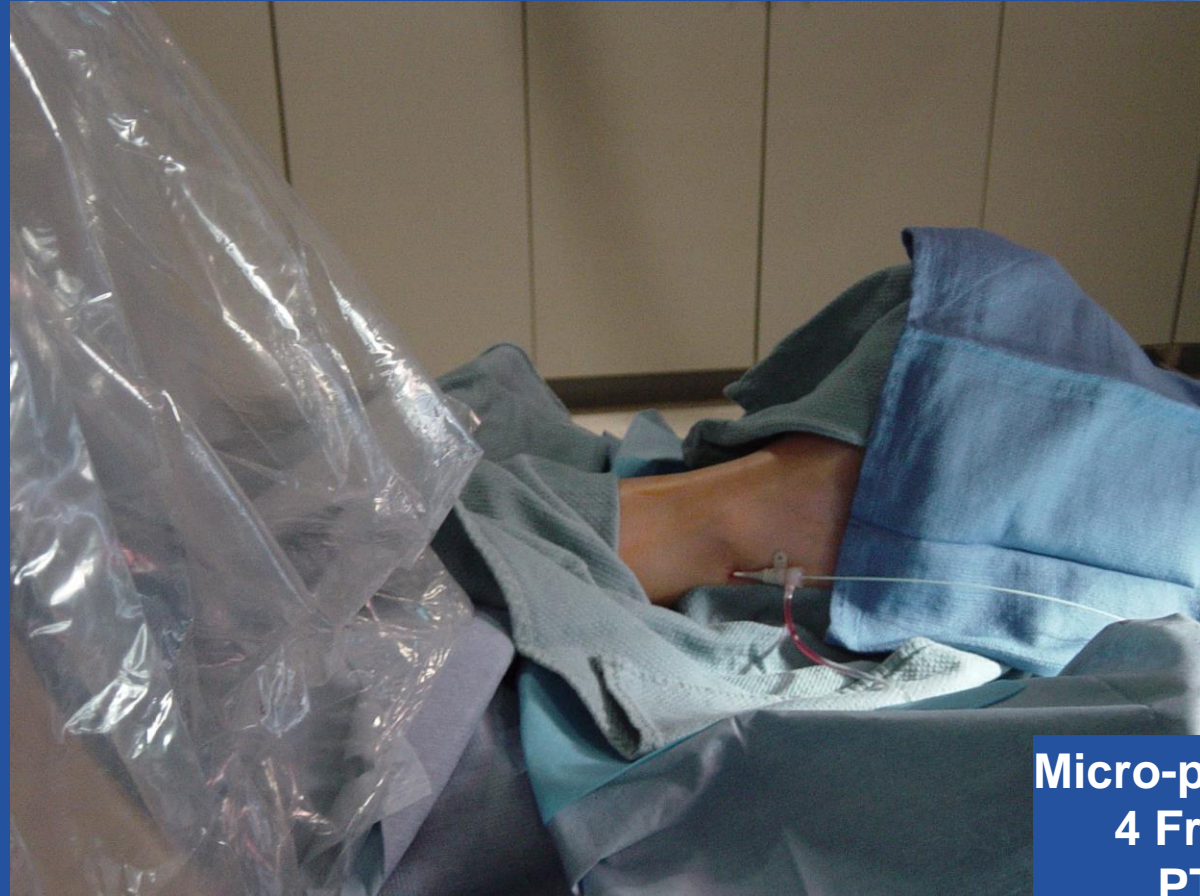- 17 yr old female sudden onset of Left leg/thigh swelling on BCP
- H/O L leg pain with running
- Venous duplex: Ilio-femoral DVT
- Despite Heparin has severe pain and swelling



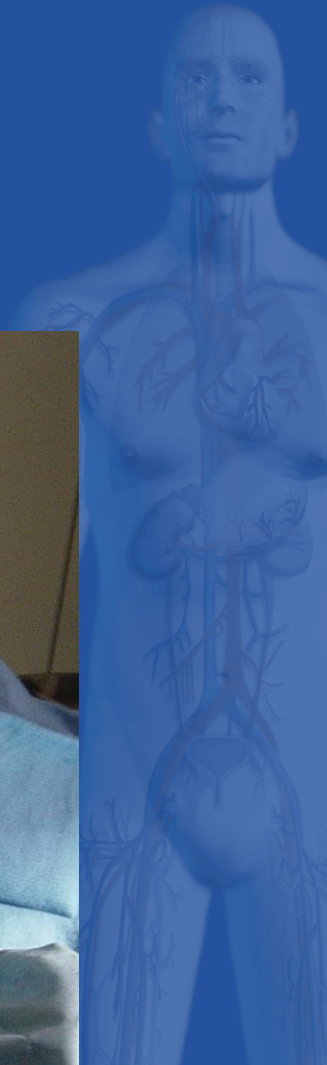
??



# Left Ilio-Femoral DVT 4 Fr AngioJet with TPA

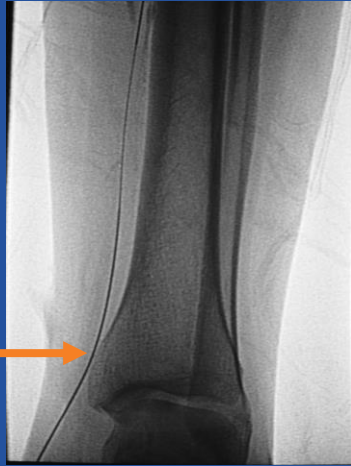


Micro-puncture kit  
4 Fr sheath  
PT vein

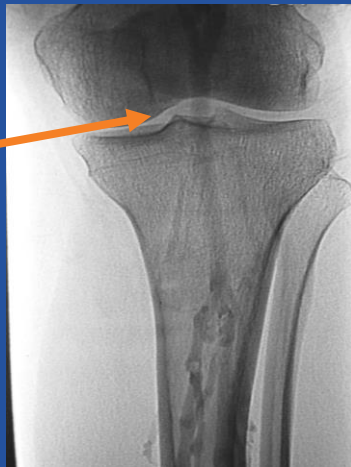

# Left Ilio-Femoral DVT 4 Fr AngioJet with TPA

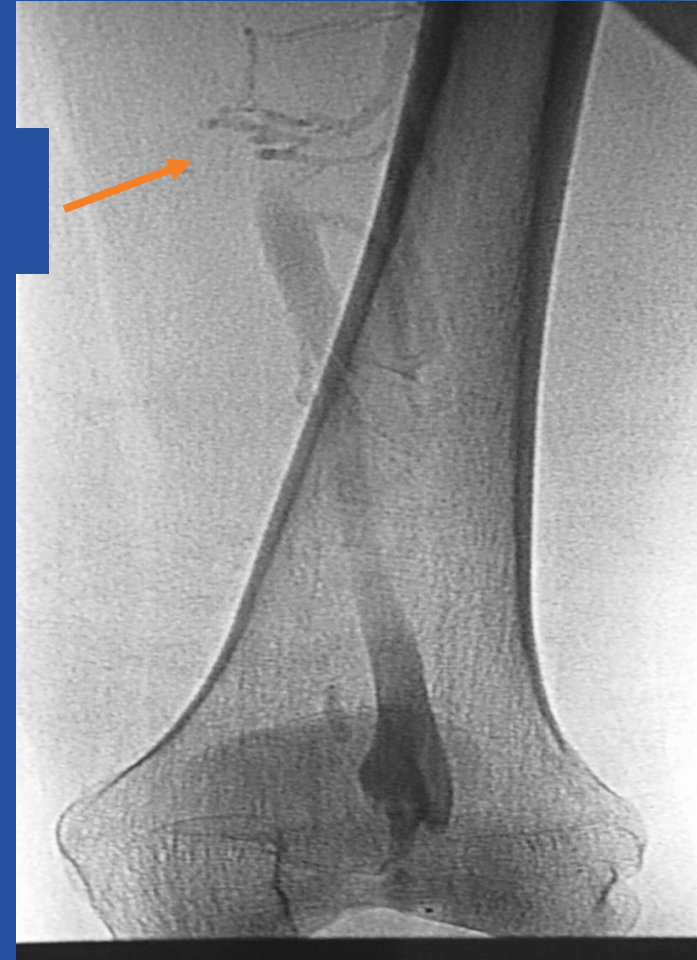Micro-puncture  
PT vein



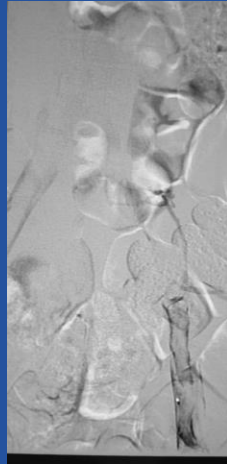
Pop vein



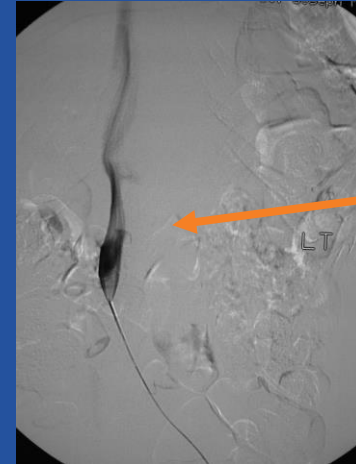
SFV



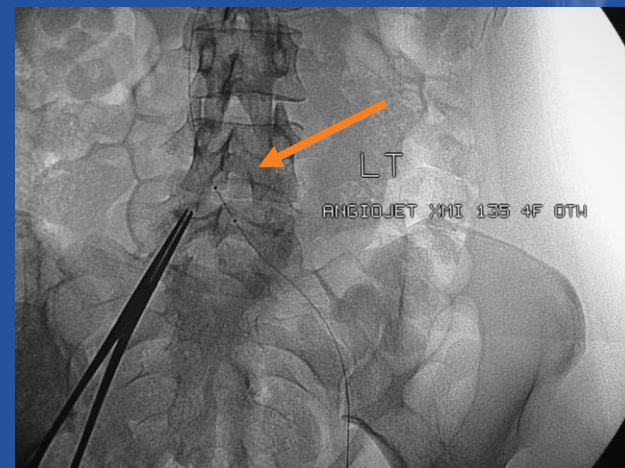
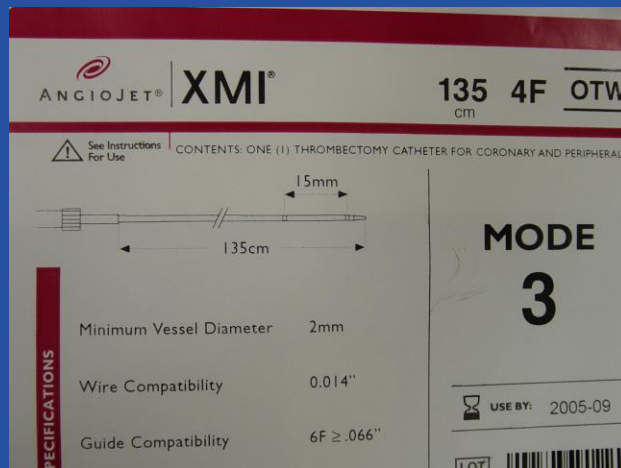# Left Ilio-Femoral DVT 4 Fr AngioJet with TPA



Clot in  
Iliac vein

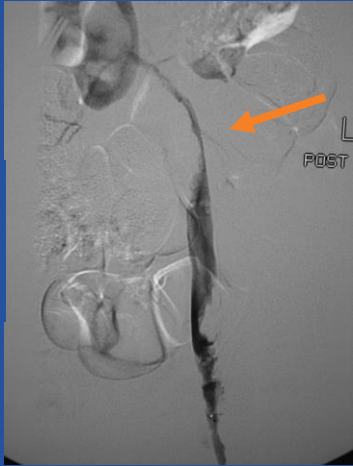

IVC

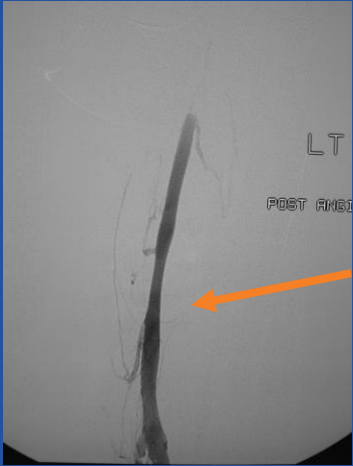

# Left Ilio-Femoral DVT 4 Fr AngioJet with TPA

First Pass



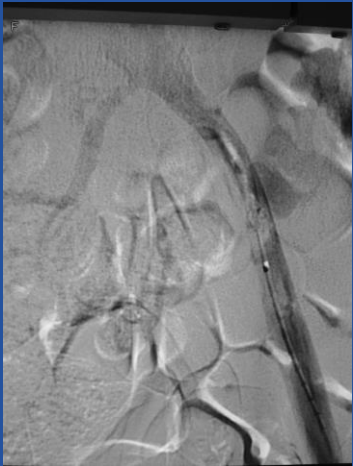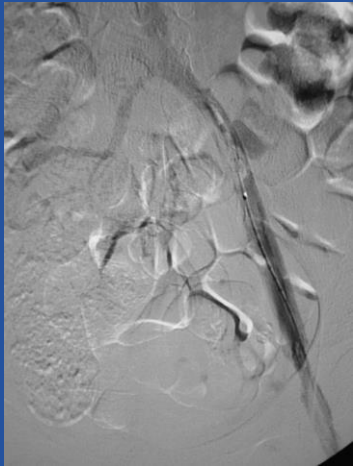Iliac V.



SFV

Pulse-Spray TPA  
And AngioJet

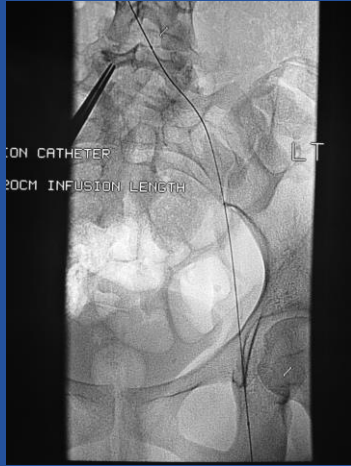
2<sup>nd</sup> pass



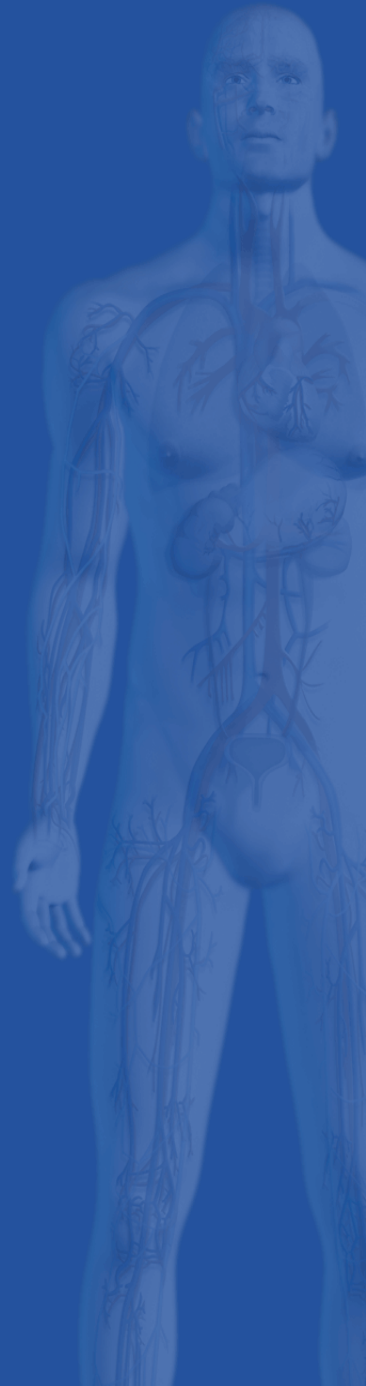
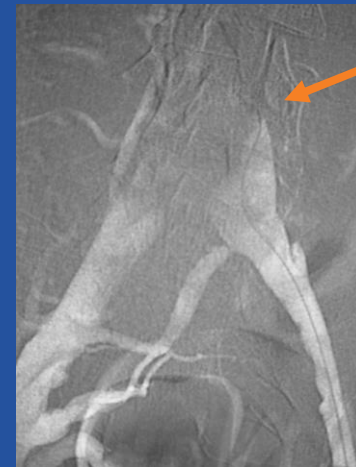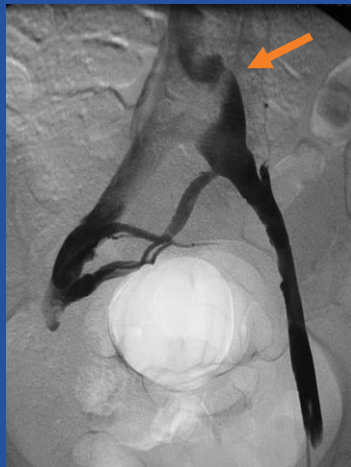

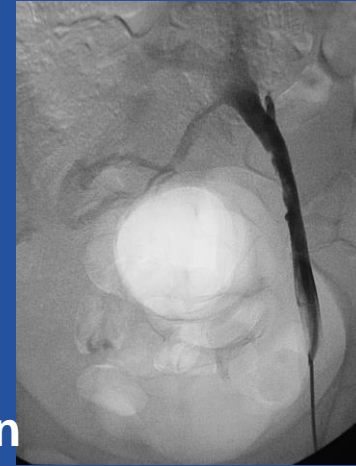
# Left Ilio-Femoral DVT 4 Fr AngioJet with TPA

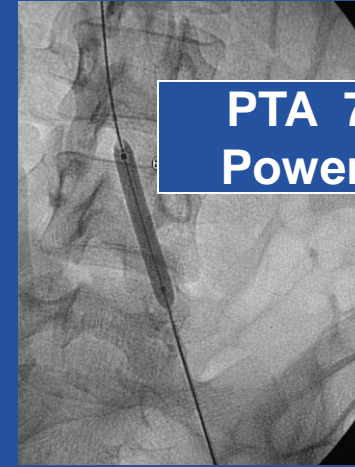
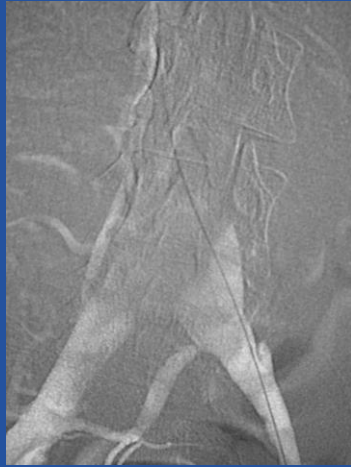
4 Fr Infusion  
catheter



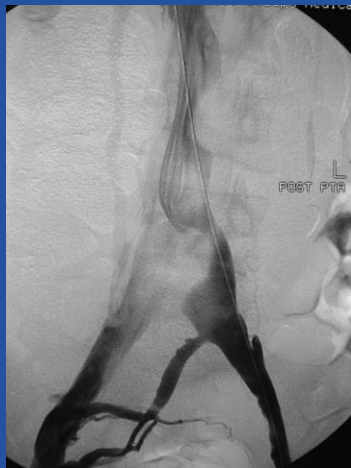24 hr TPA infusion  
.50 mg/hr



# Left Ilio-Femoral DVT 4 Fr AngioJet with TPA



**PTA 7X4  
Powerflex**



**D/C on  
Coumadin  
+ factor V  
(heterozyg)**



