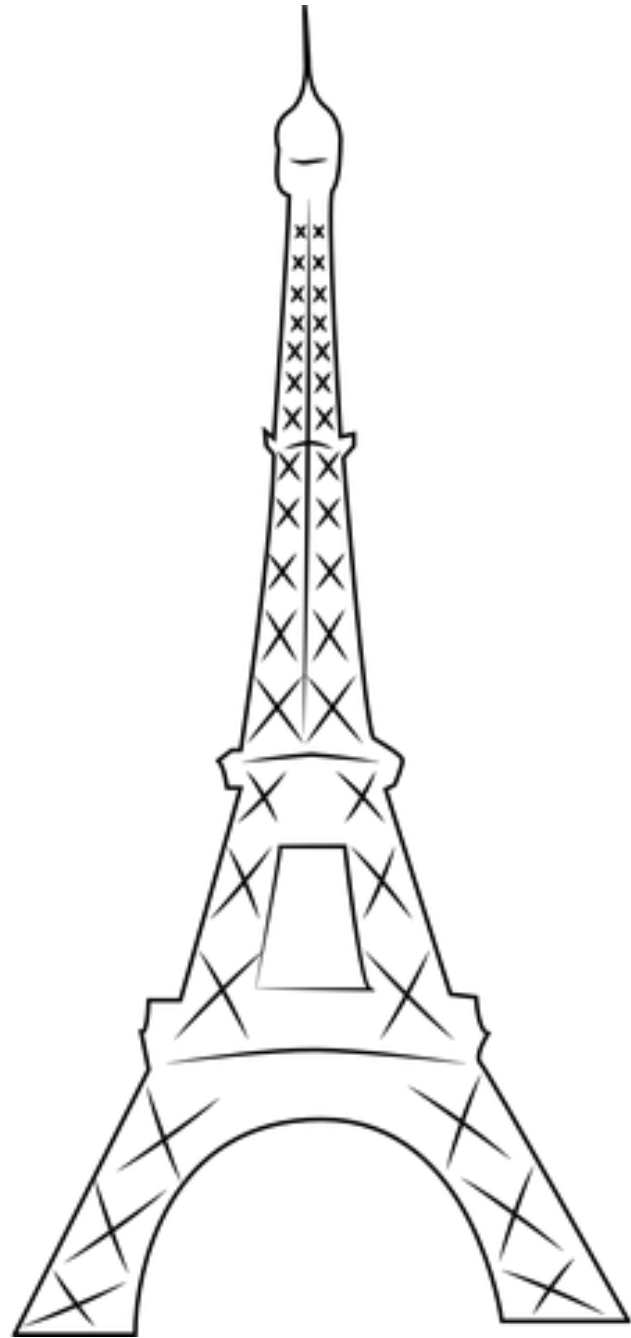


Controversies & updates in Vascular Surgery

Paris - january 23-25 2020



Venous session

Sciatic nerve varices
pathogenesis & duplex investigation

Philippe LEMASLE

Le Chesnay - France

Disclosure

Speaker name :

..... LEMASLE Philippe

I do not have any potential conflict of interest

1 - pathogenesis

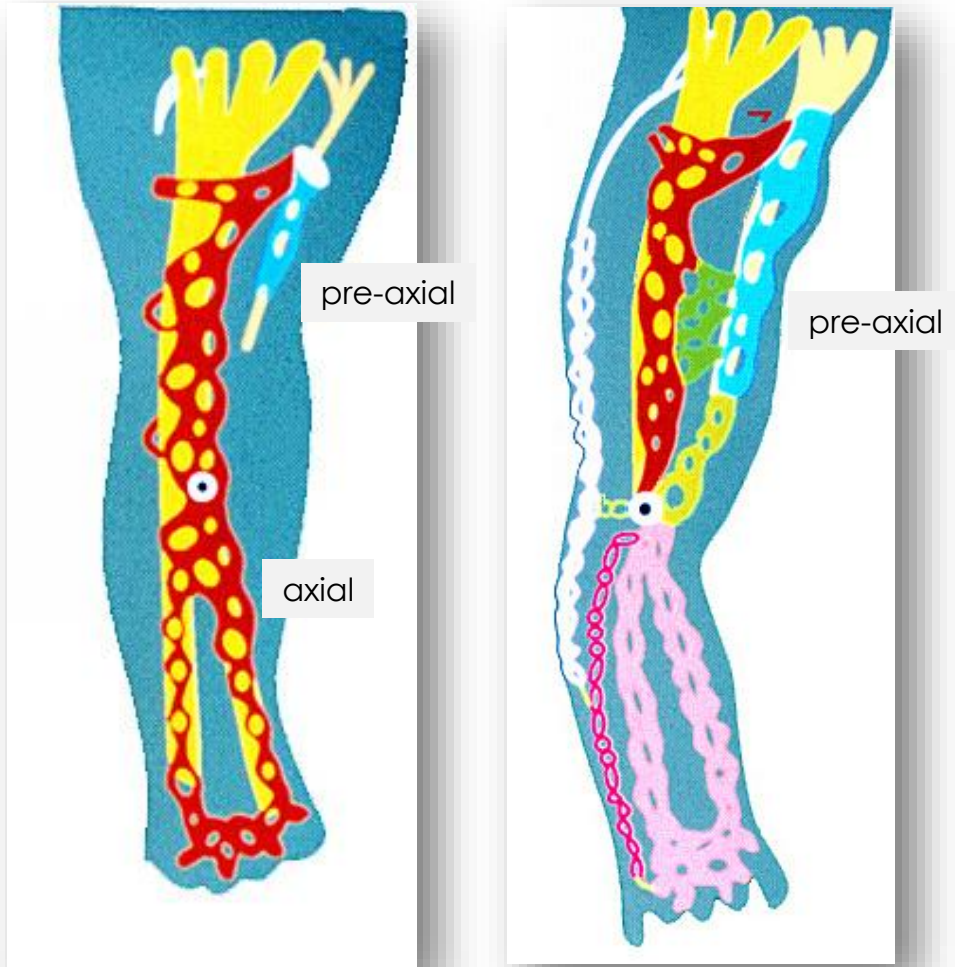
- Neuroangiogenesis = professor Gillot's theory

During embryological development

- first, appearance of the undifferentiated capillary plexuses
- after appearance of the nerves and at their contact
 - >> embryonic venous plexuses will concentrate and differentiate
- 3 main angiogenic nerves are involved in venous embryogenesis
 - embryologic axial nerve >> sciatic nerve
 - embryologic pre-axial nerve >> femoral nerve
 - embryologic post-axial nerve >> posterior femoral cutaneous nerve

neuro-angio-genesis

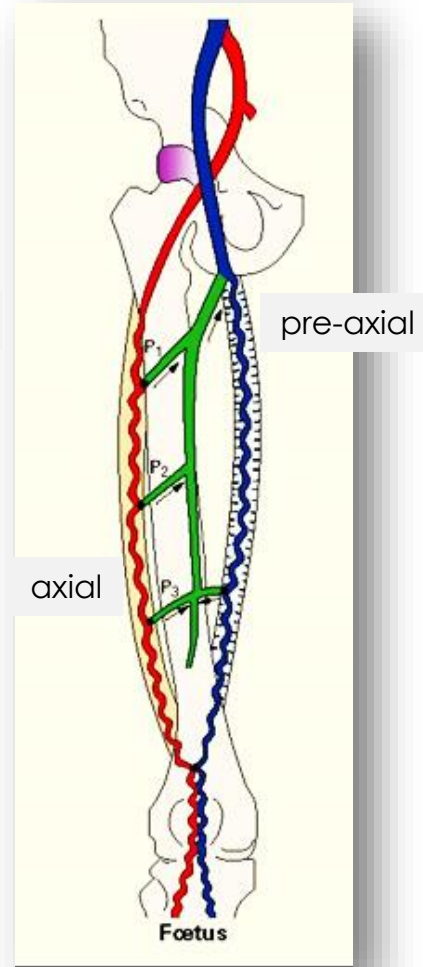
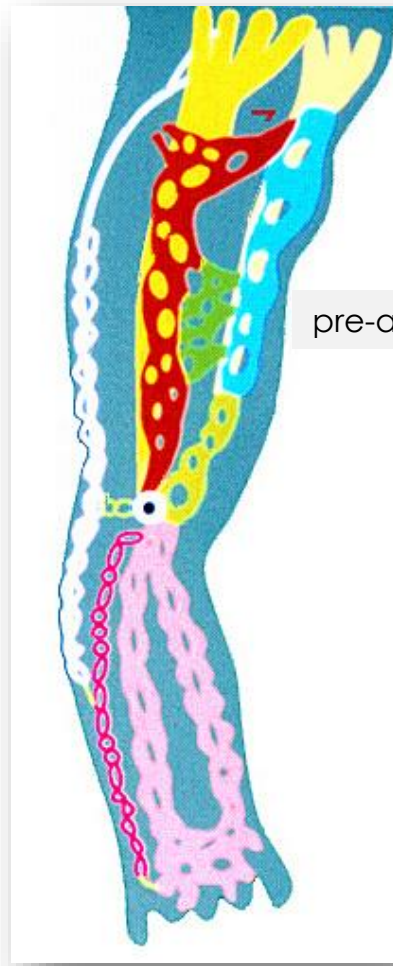
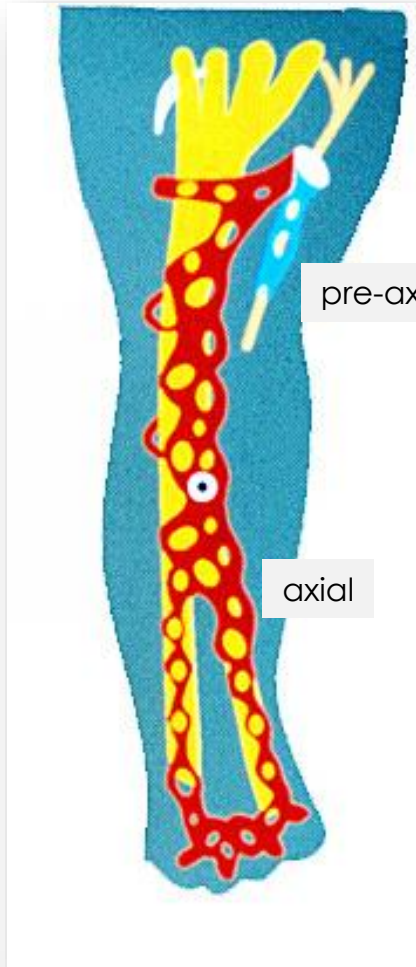
professor Gillot's diagrams



embryological venous disposition

neuro-angio-genesis

professor Gillot's diagrams



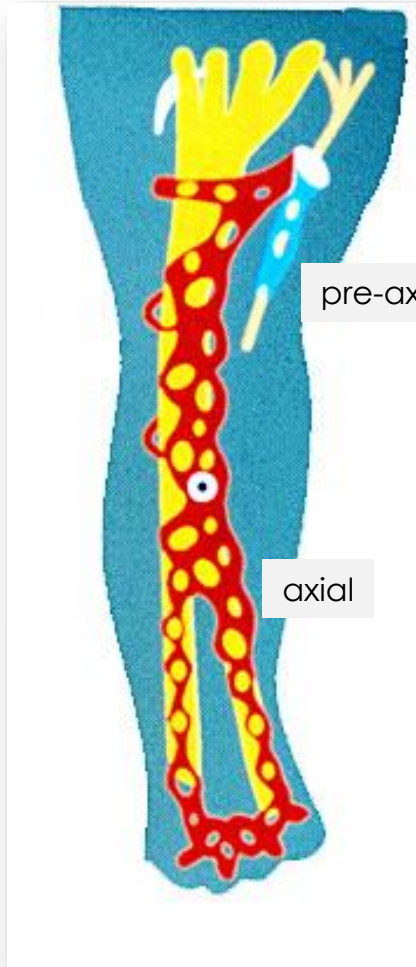
embryological venous disposition

fetal venous
disposition

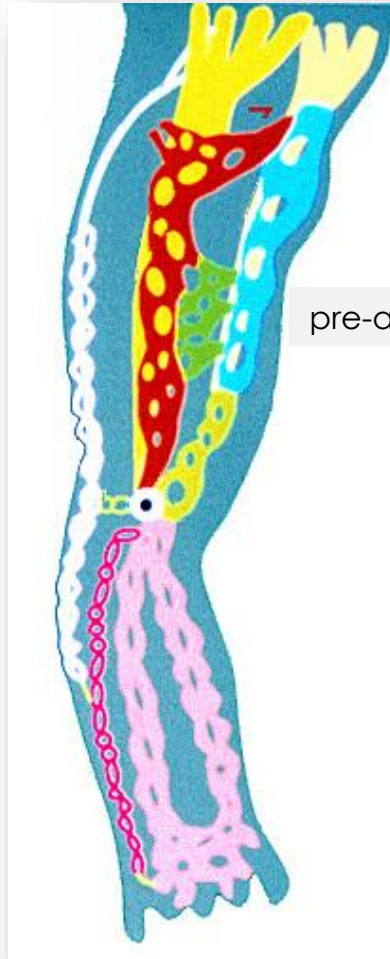
neuro-angio-genesis

professor Gilot's diagrams

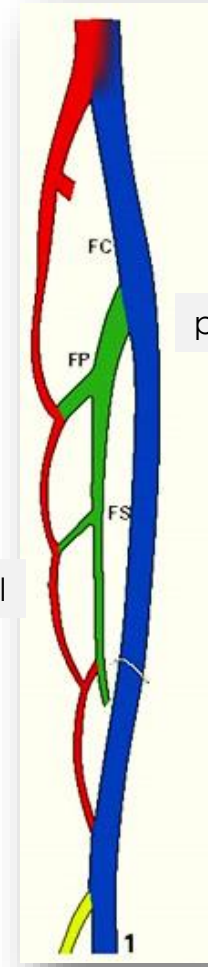
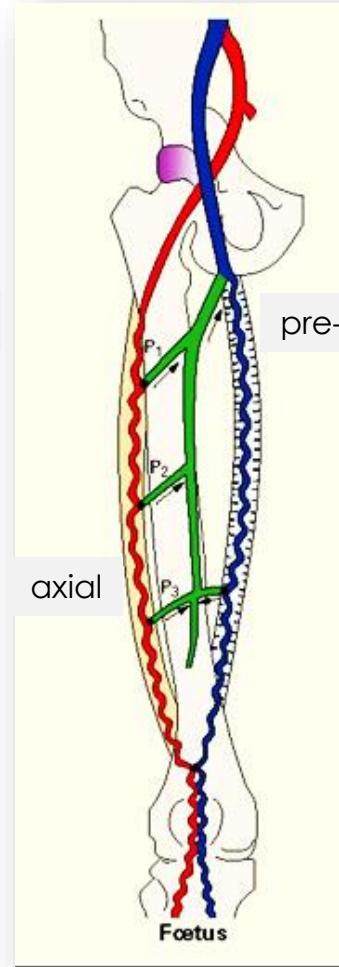
normal anatomical disposition



embryological venous disposition



fetal venous disposition

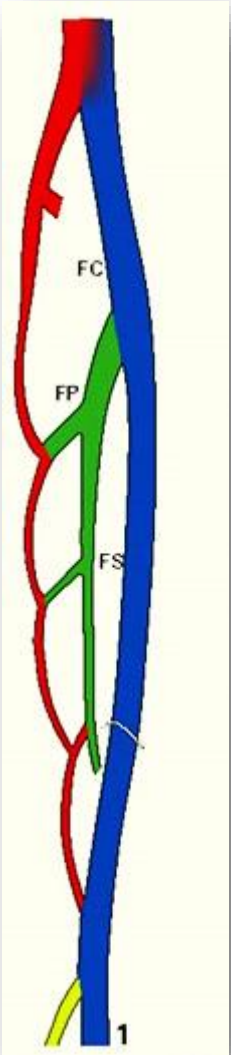


adult venous anatomy

– DEVELOPPMENT
PRE AXIAL system

– REGRESSION
AXIAL system

neuro-angio-genesis



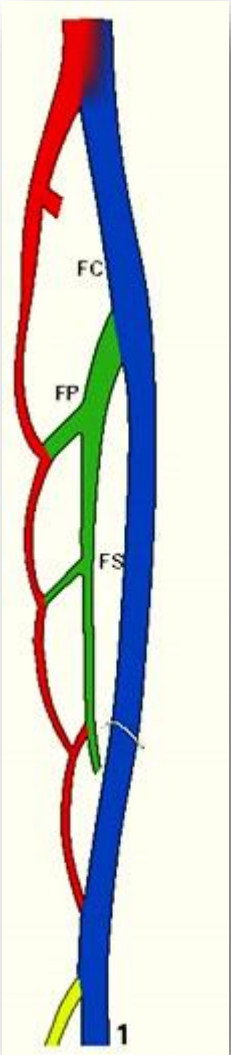
– **DEVELOPMENT**
PRE-AXIAL system

– **REGRESSION**
AXIAL system

- femoral vein is the main route for venous drainage of the lower limb

- axial system is reduced to simple discontinuous arches, that communicate with the deep femoral vein

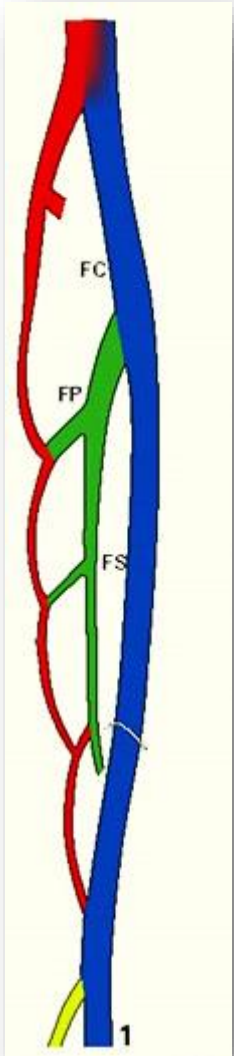
neuro-angio-genesis



– **DEVELOPMENT**
PRE-AXIAL system

– **NON REGRESSION**
AXIAL system

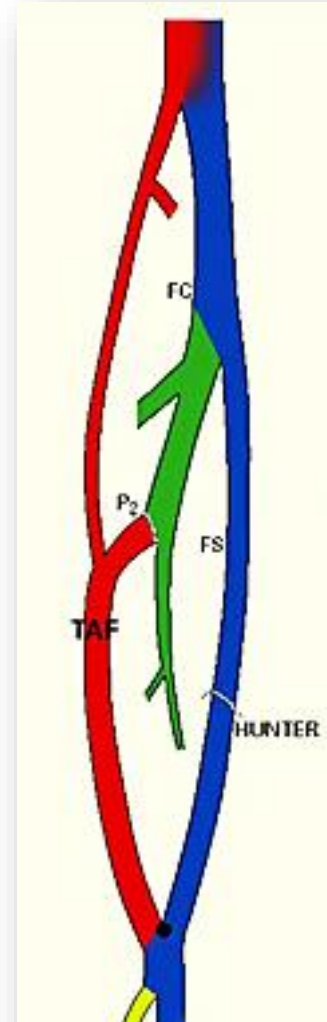
neuro-angio-genesis



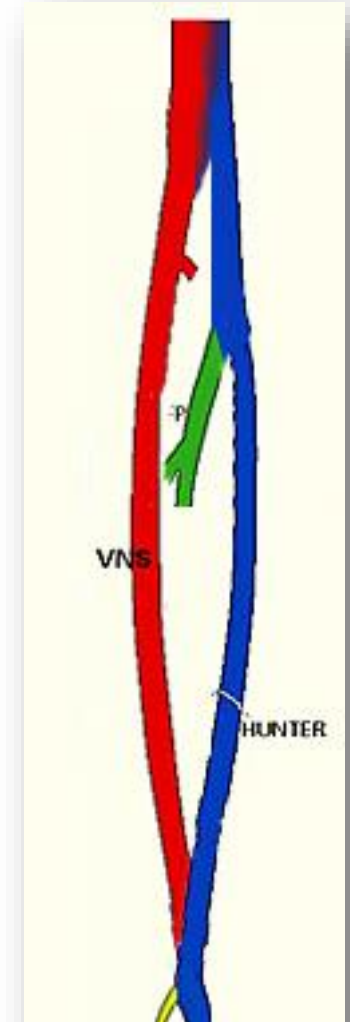
– DEVELOPMENT
PRE-AXIAL system



– NON REGRESSION
AXIAL system



axo-femoral trunk




persistent sciatic vein

modal disposition

anatomical variation


neuro-angio-genesis



– **DEVELOPMENT**
PRE-AXIAL system

– **NON REGRESSION**
AXIAL system

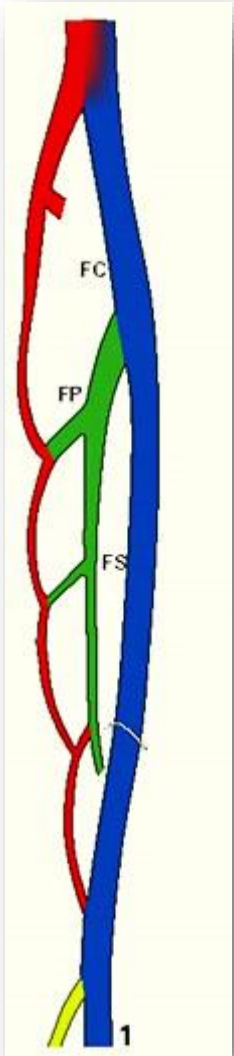
neuro-angio-genesis



– **NON DEVELOPMENT**
PRE-AXIAL system

– **NON REGRESSION**
AXIAL system

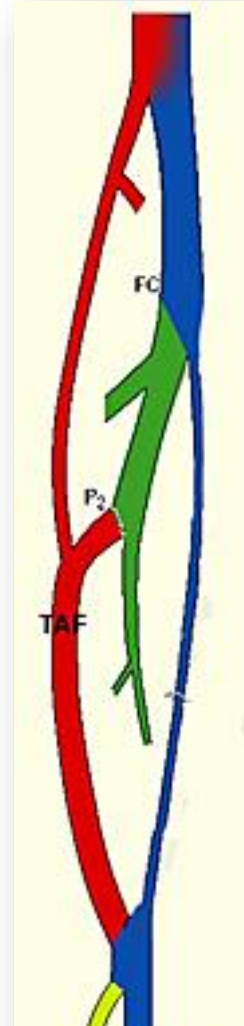
neuro-angio-genesis



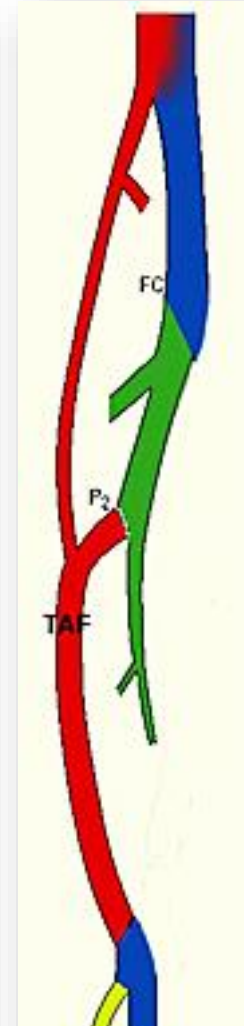
– **NON DEVELOPMENT**
PRE-AXIAL system



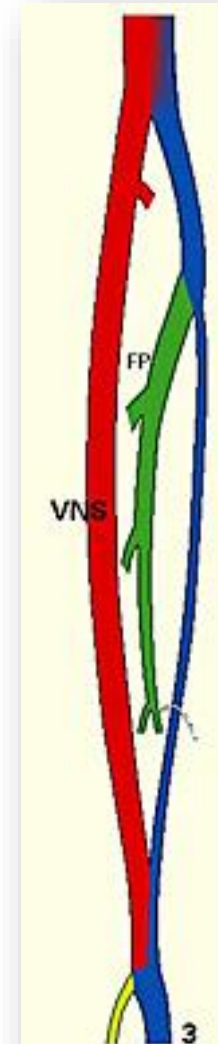
– **NON REGRESSION**
AXIAL system



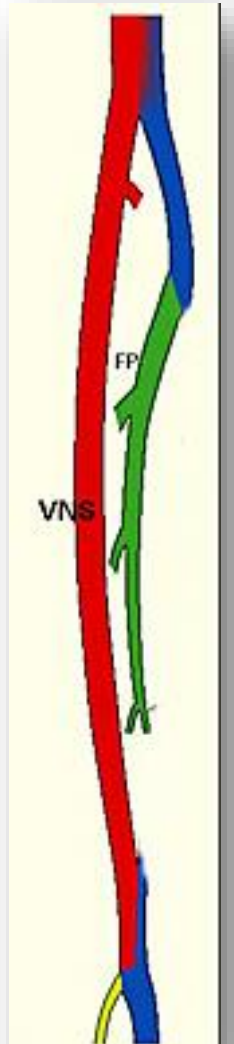
axo-femoral trunk



anatomical variation

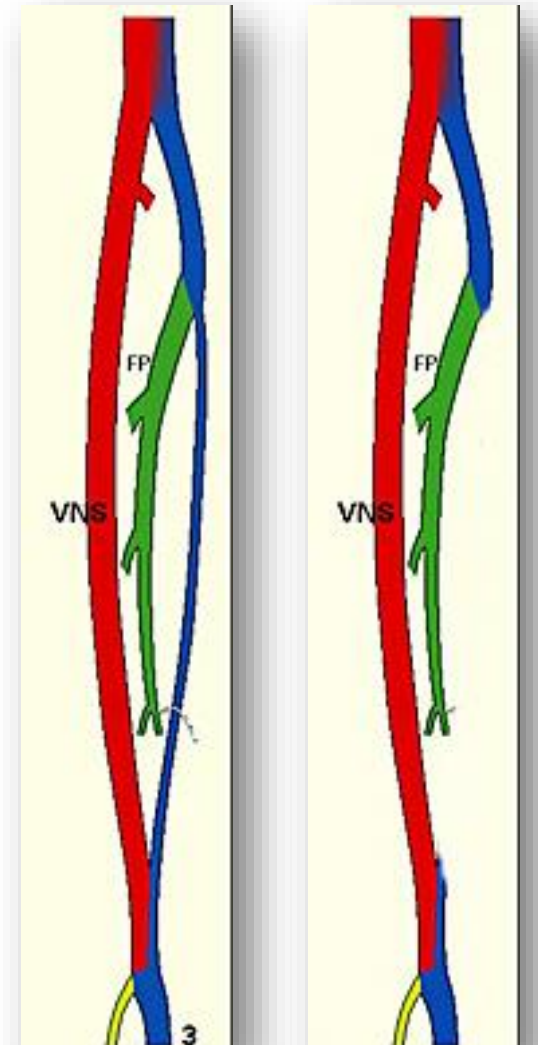


persistent sciatic vein
PSV



neuro-angio-genesis

persistent sciatic vein is only a rare modality
of sciatic nerve varicosis

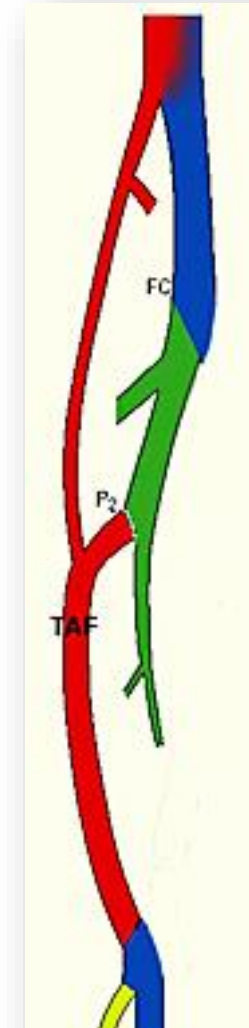


persistent sciatic vein
PSV

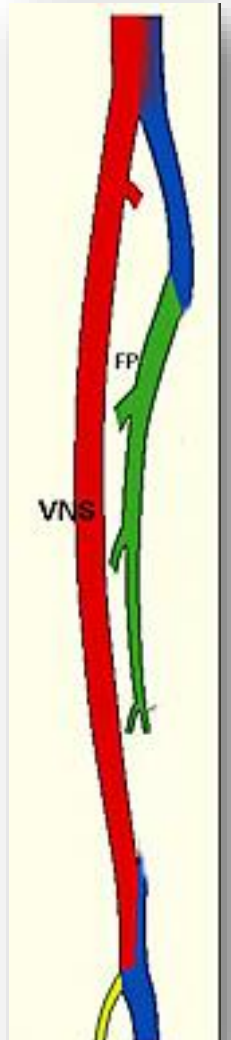
anatomical variation

neuro-angio-genesis

if the embryonic vein persists, always check
for the presence of the femoral vein



axo-femoral trunk



persistent sciatic vein
PSV

anatomical variation


2 - duplex investigation

- ultrasonic aspect

= anatomical disposition

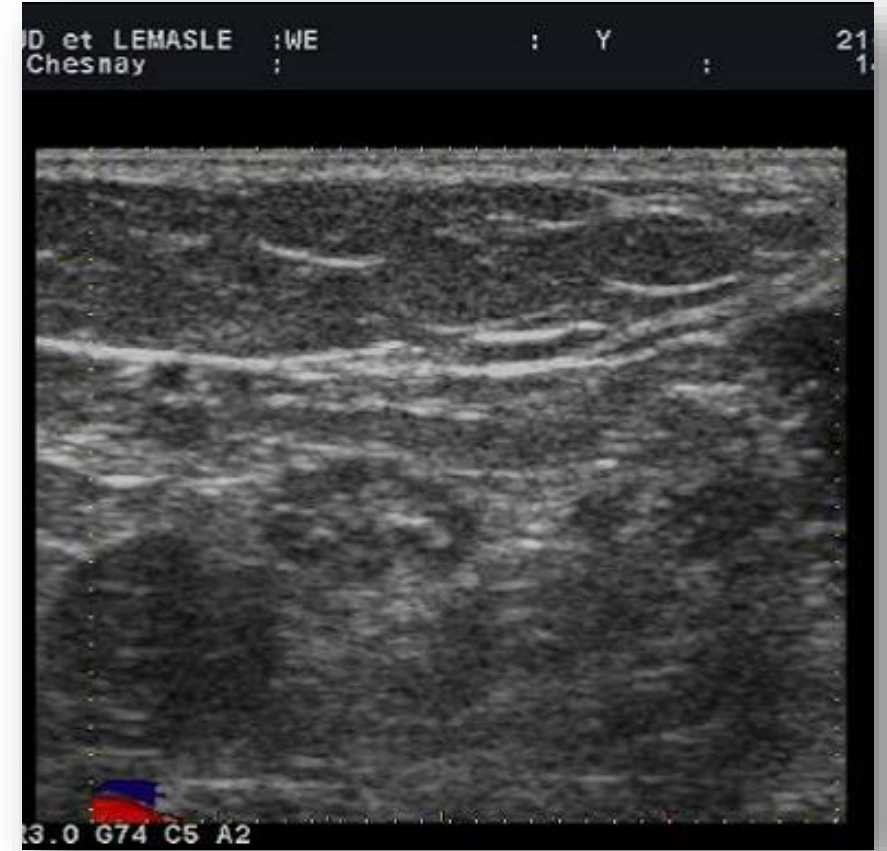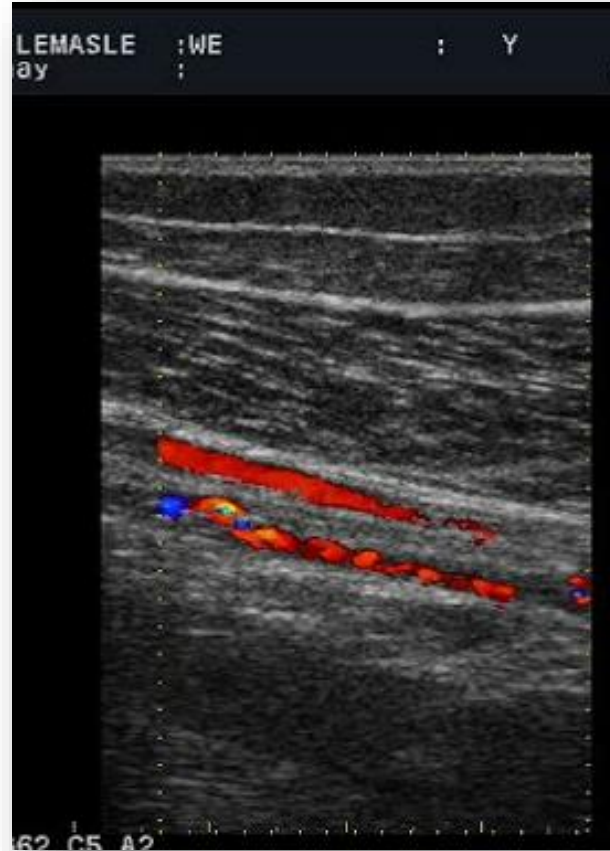
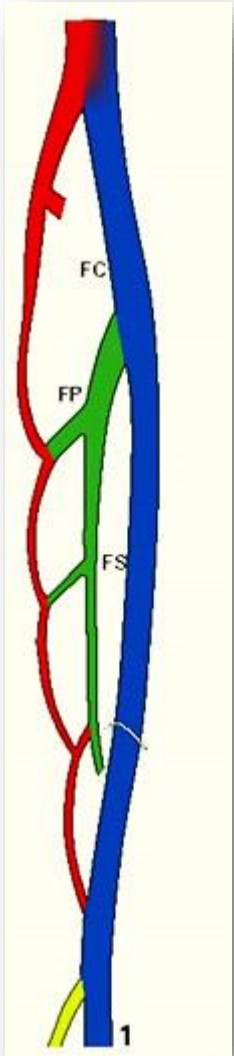
= embryological evolution

2 - duplex investigation



modal disposition

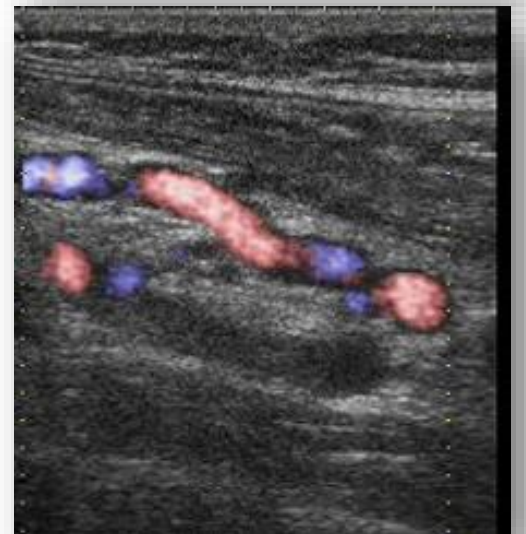
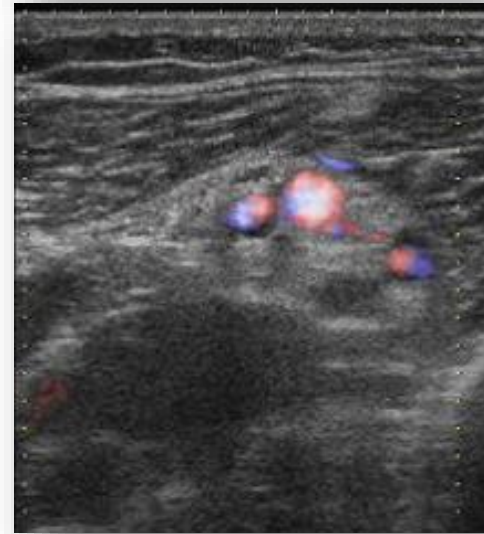
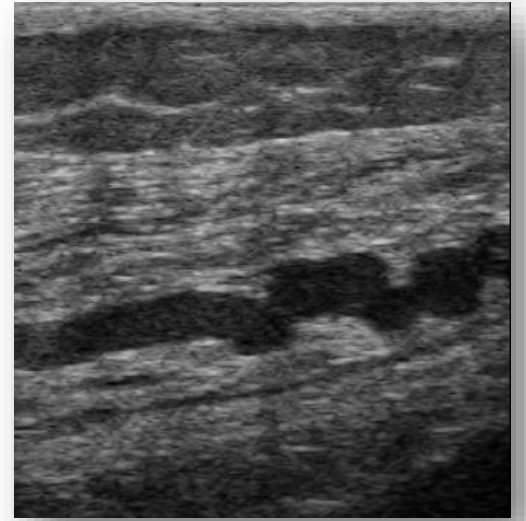
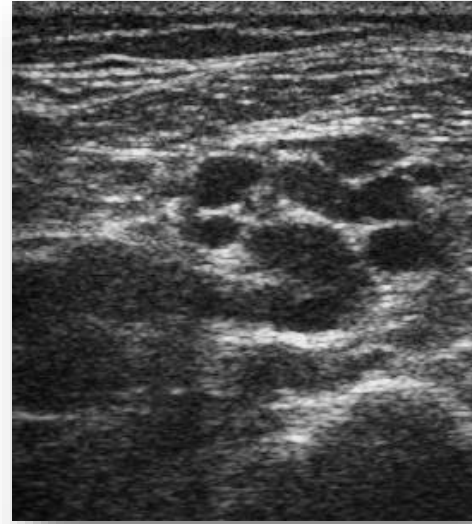
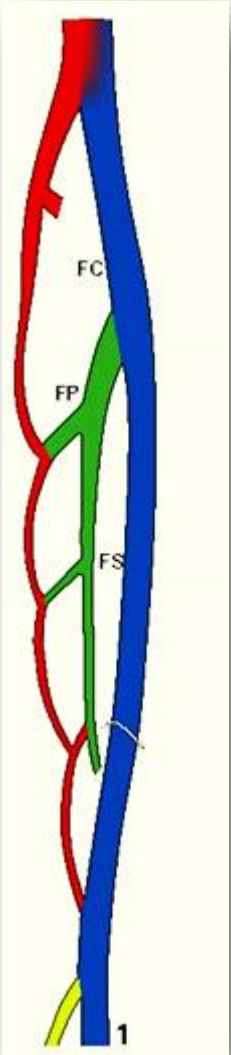
2 - duplex investigation



small caliber, contoured, refluxing, multivessel network
located within the nerve sheath

modal disposition

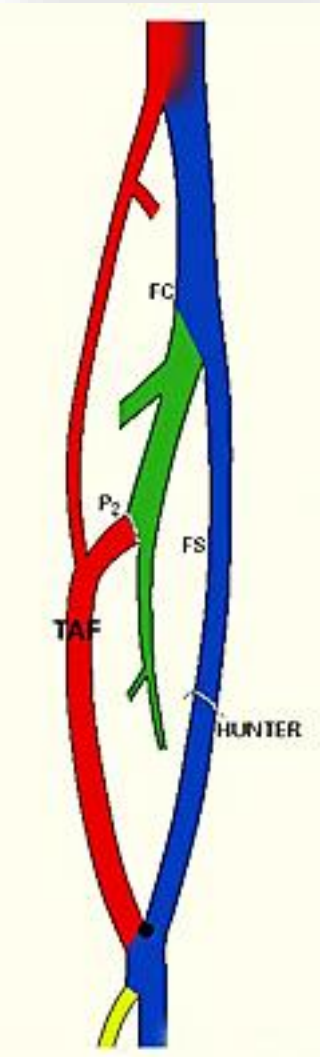
2 - duplex investigation



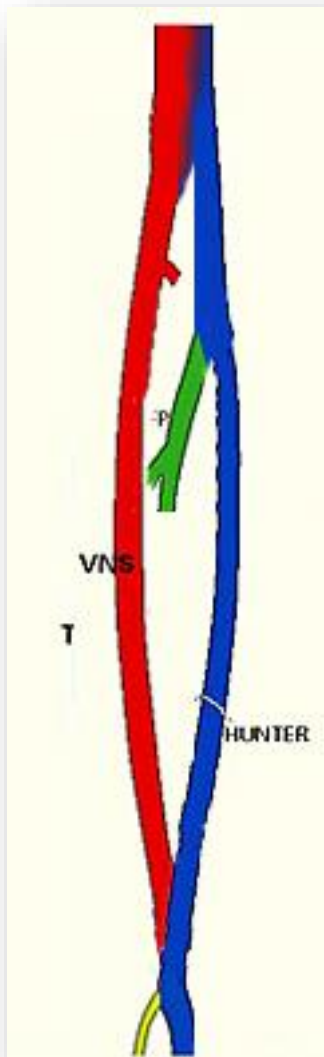
modal disposition

this multivessel network can be **dilated** in the nerve sheath

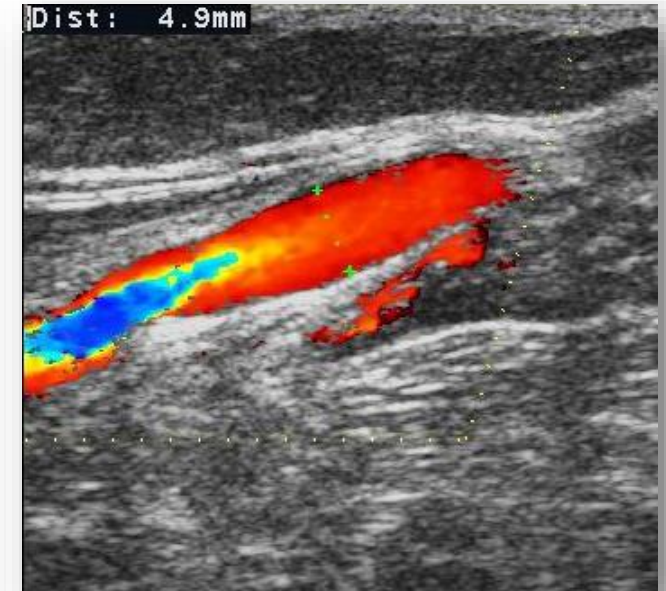
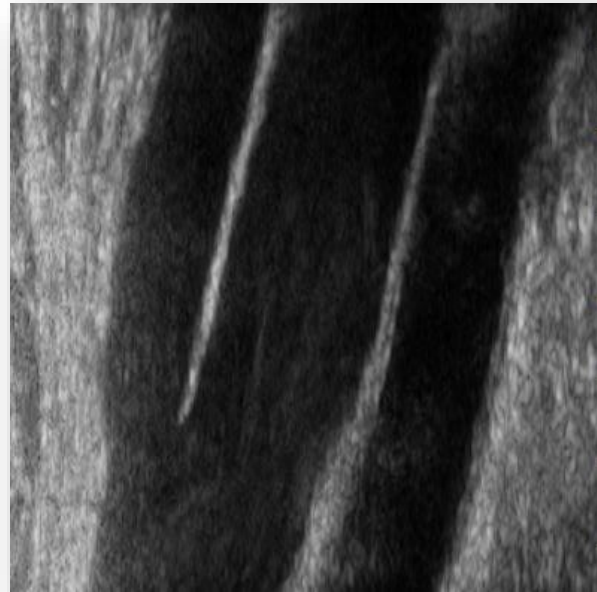
2 - duplex investigation



axo-femoral
trunk

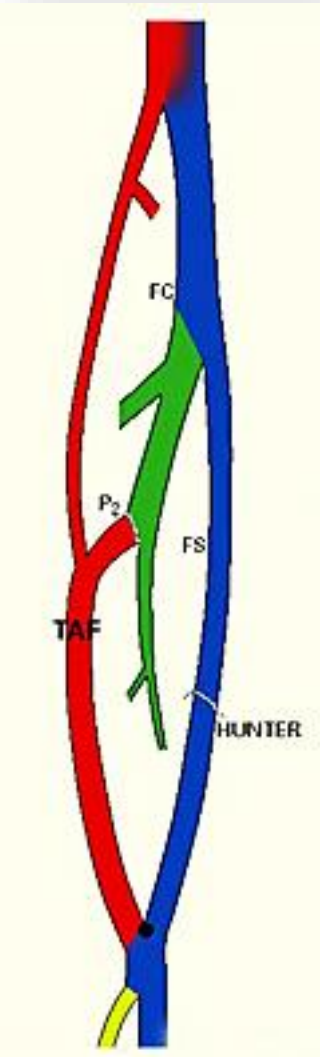


persistent
sciatic vein

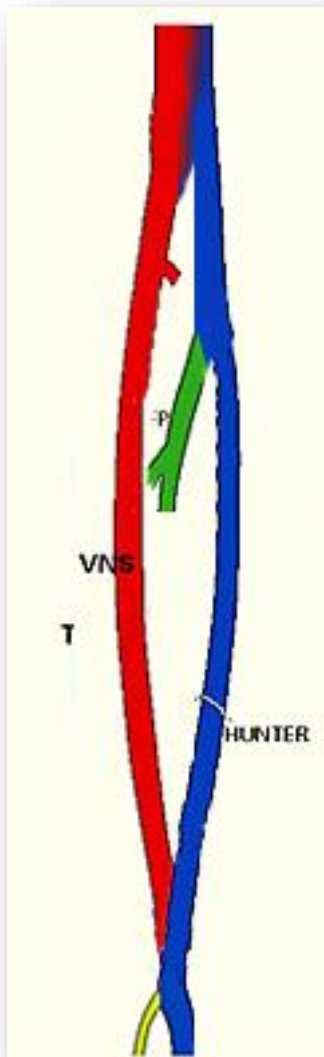


extension of the popliteal vein by 2 equivalent axes
femoral vein and axiofemoral trunk ou PSV

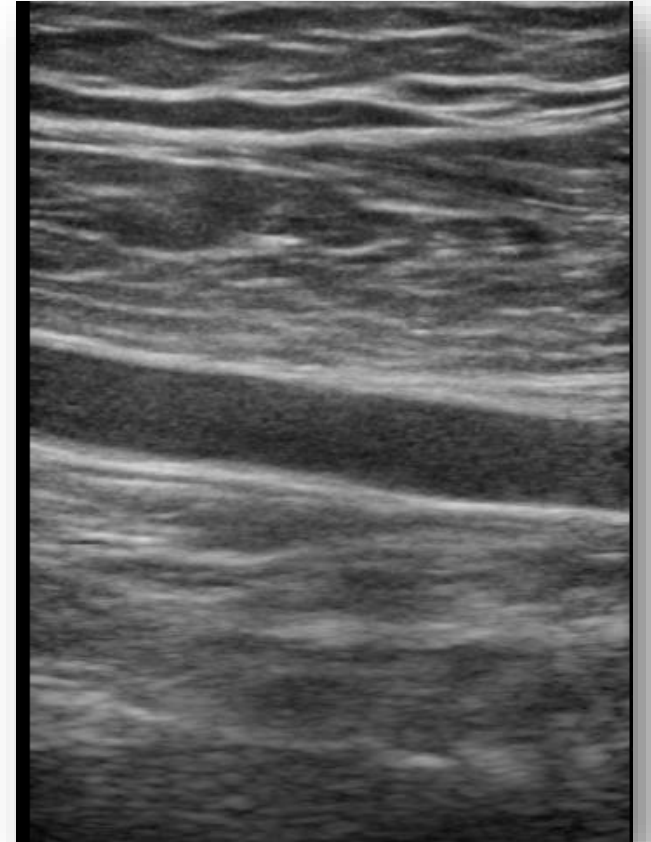
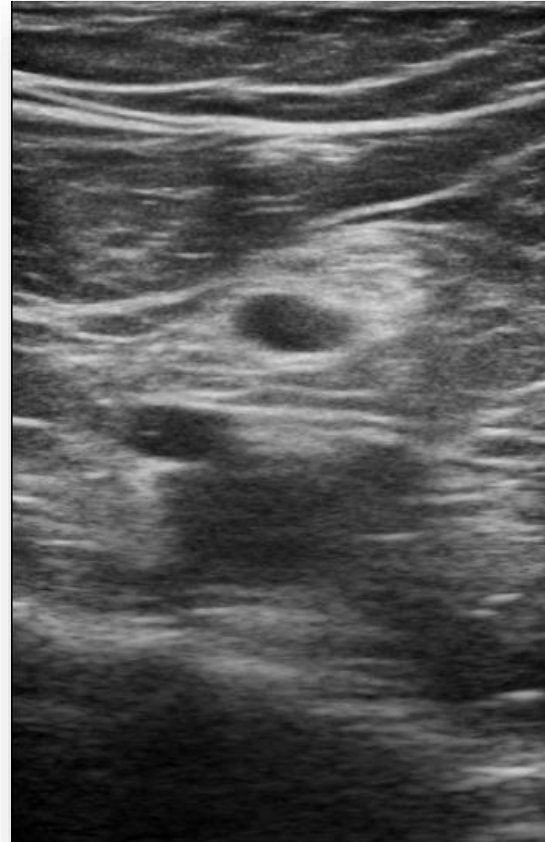
2 - duplex investigation



axo-femoral
trunk

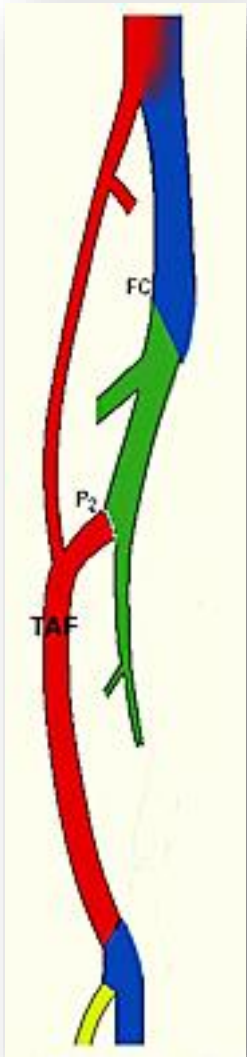


persistent
sciatic vein

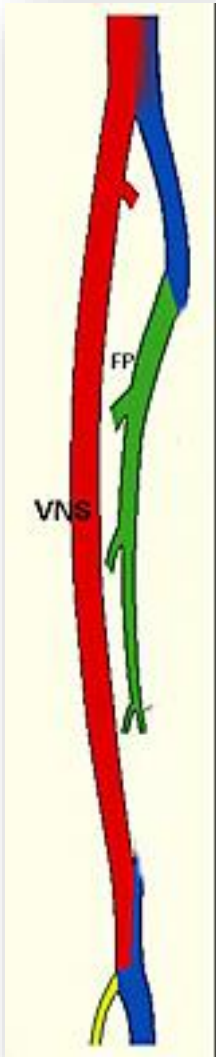


monotoncular axis
in contact with the sciatic nerve

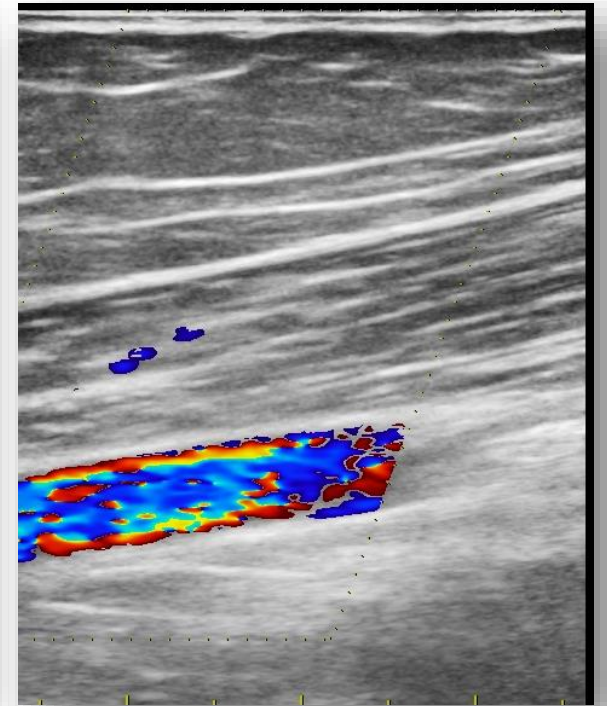
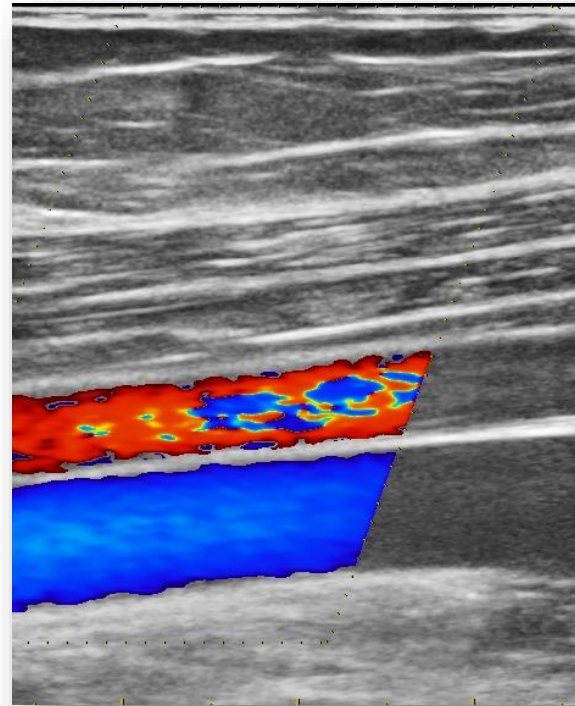
2 - duplex investigation



axo-femoral
trunk

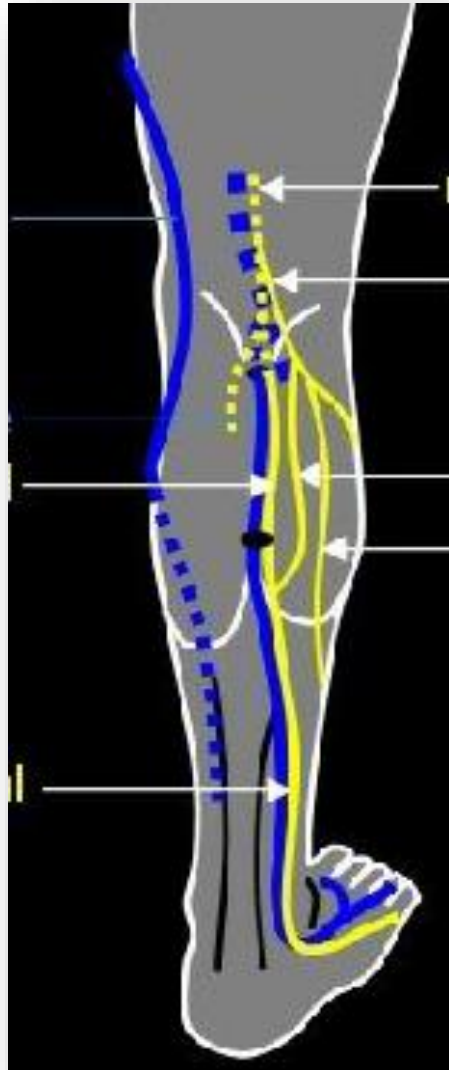
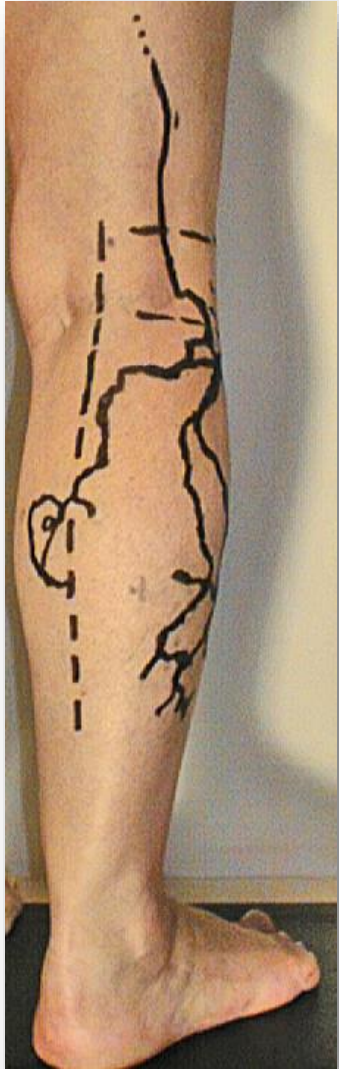

persistent
sciatic vein



if the embryonic vein persists, always check
for the **presence of the femoral vein**

2 - duplex investigation

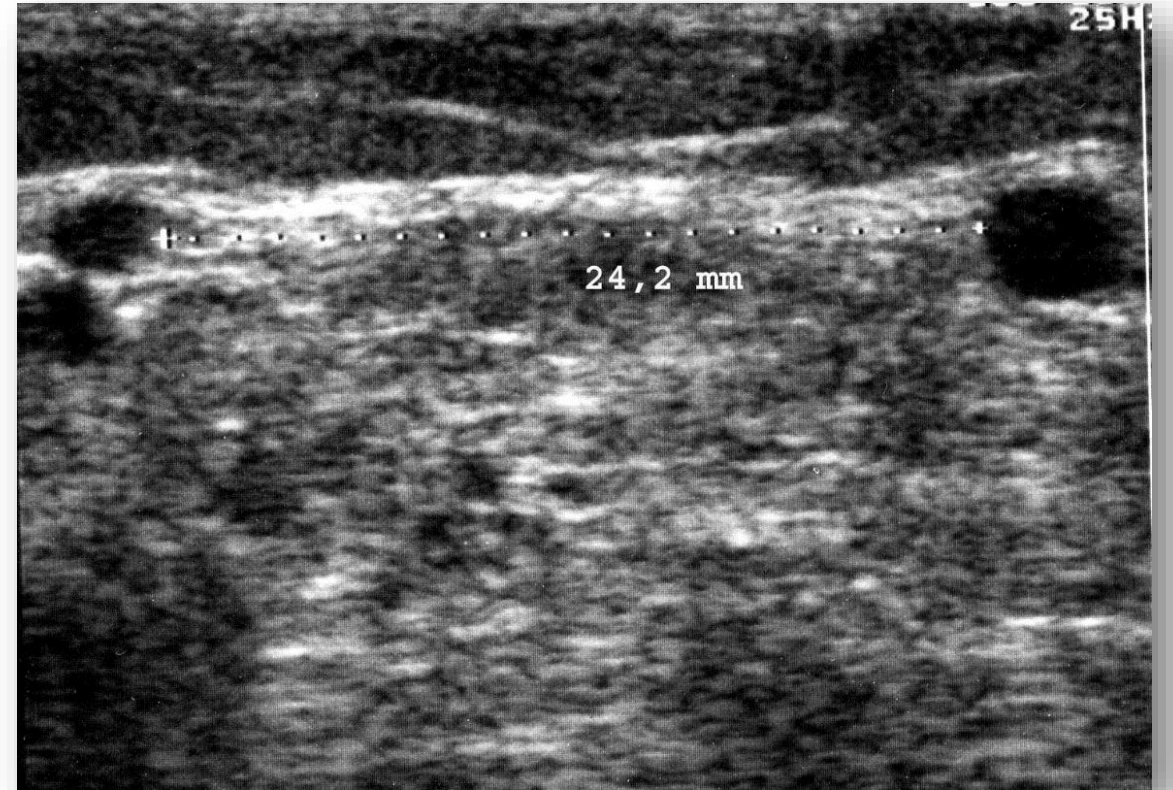


sciatic nerve

common fibular
nerve

communicating
branch

lateral cutaneous
sural nerve



a tubular trunk, located under the saphenous
fascia, parallel & outside the SSV, incontinent
= pathognomonic criterion of sciatic nerve varicosis

Conclusion

- Duplex scan is sufficient for a positive diagnosis and characterize the sciatic nerve varicosis
- Persistent sciatic vein is only a rare modality of sciatic nerve varicosis
- In front of a truncular forme of sciatic nerve varicosis, check for the presence of the femoral vein
- To the leg, there is a pathognomonic ultrasound diagnostic criterion

Controversies & updates in Vascular Surgery

2020